

## Protective Effects of Propolis Against the Amitraz Hepatotoxicity in Mice

<sup>1</sup>Attalla F. El-Kott and <sup>2</sup>Ayman A. Owayss

<sup>1</sup>Department of Zoology, Faculty of Science,

<sup>2</sup>Department of Plant Protection, Faculty of Agriculture, Fayoum University, Egypt

**Abstract:** The present study aimed to study the protective effects of honeybee propolis against the amitraz hepatotoxicity in mice. Forty-eight Swiss albino male mice of 8 weeks of age, 22 to 25 g body weight were divided into four groups. The 1<sup>st</sup> was control, the 2<sup>nd</sup> was treated orally with 150 mg kg<sup>-1</sup> propolis extract, the 3<sup>rd</sup> was treated with 160 mg kg<sup>-1</sup> amitraz and the 4<sup>th</sup> one had 160 mg kg<sup>-1</sup> amitraz + 150 mg kg<sup>-1</sup> propolis extract. These daily treatments lasted for 8 weeks and laboratory assays were measured weekly. Results, after mice sacrificed, histopathology and immunohistology tests were carried out. The obtained results revealed that amitraz had affected liver biochemicals concentrations, whereas propolis led to a significant decrease in these levels in treated group. But, hepatocytes of mice treated with amitraz + propolis demonstrated positive stained nuclei, by using Ki67 immunostaining, less than those of amitraz treated only. The study suggests that propolis ameliorated the recovery of hepatotoxicity of amitraz in the tested mice.

**Key words:** Amitraz, propolis, hepatoprotective, Ki67, proliferation, liver functions

### INTRODUCTION

Amitraz, [1, 5-di-(2, 4-dimethylphenyl)-3-methyl-1, 3, 5-triaza-penta 1, 4-diene], is a member of the formamidine pesticides, used worldwide as insecticide and acaricide (Hollingworth, 1976). It is a veterinary medicinal product used by beekeepers to control the ectoparasitic mite, *Varroa destructor* (formerly: *V. jacobsoni*) which is a wide spread parasite feeds on hemolymph of mature and immature stages of honey bees and damages beehives seriously. The toxicity of amitraz has not been investigated at a sufficient level, but when administered orally or by skin washing, it is absorbed at a high rate. For this reason, the toxicity risk was considered to be high (Grossman, 1993). Also, the insecticide interacts with the  $\alpha$ -2-adrenoceptor and produces behavioral, physiological and biochemical effects. Amitraz inhibited brain monoamine oxidase activity and motor function in rats (Moser and MacPhail, 1986) and decreased glutathione content in mouse livers (Costa *et al.*, 1991). The reported effects of amitraz poisoning in humans include central nervous system depression, bradycardia, hypotension, vomiting, hyperglycaemia, glycosuria, polyuria and miosis (Jorens *et al.*, 1997 and Gamier *et al.*, 1998).

Use of propolis by humans has a long history, predated only by the discovery of honey. Propolis contains 50-70% resins and 10% essential oils, coming from the trees, mixed with 30-50% wax for proper consistency and 5-10% pollen, acquired from being transported in the bees's pollen baskets (<http://www.bioliplus.com/library/propolis.html>, 2000). The worker bees apply the resin to seal any cracks and fissures in the hive and they line their front door with it to prevent contamination. They use it as an antiseptic in breeder cells and they mix propolis with wax to distribute a fine varnish over every inch of the hive to protect it (Burdock, 1998). So far, 150 compounds have been identified from propolis (Greenaway *et al.*, 1991). The main chemical classes found in propolis are flavanoids,

---

**Corresponding Author:** Dr. Attalla F. El-Kott, Department of Zoology, Faculty of Science, Fayoum University, Fayoum, Egypt Tel:+20502536868 Fax:+20846370025

phenolics and various aromatic compounds. However, propolis contains many of the B-complex vitamins, important minerals and trace elements. But its bioflavanoid content is now receiving attention. Bioflavanoids are antioxidant molecules that play very important role in the scavenging of free radicals, which are produced in degenerative heart diseases, atherosclerosis, aging and effects of toxic substances, e.g., ethyl alcohol (<http://www.nutritionreporter.com/antioxidants.html>; <http://www.nutritionreporter.com/soy-isoflavones.html>). At least 38 flavanoids have been found in propolis (Schmidt and Buchmann, 2000). The chemical composition of propolis is highly variable because of the broad range of plants visited by honey bees while collecting the substance. Propolis is relatively non-toxic, with a no-effect level (NOEL) in a 90 day's mouse study of 1400 mg kg<sup>-1</sup> body weight/day (Burdock, 1998). Propolis has been shown to stimulate various enzyme systems, cell metabolism, circulation and collagen formation, as well as it improves the healing of burn wounds. These effects have been shown to be the result of the presence of arginine in propolis. It was reported that propolis stimulated an immune response in mice (Young, 1987). It activates immune cells that produce cytokines. Bee propolis is one of the most promising extracts as antitumor agent. Many researches proved its anti viral, anti-bacterial, anti-inflammatory and immunostimulating activities (Wang *et al.*, 2005).

So, the aim of the present study was to evaluate the prospective protection of bee propolis against the amitraz hepatotoxicity in mice.

## MATERIALS AND METHODS

### Propolis Extraction

Crude propolis was obtained from honey bee, *Apis mellifera carnica*, colonies situated at the apiary of Faculty of Agriculture at Fayoum, Egypt. Samples were weighed, homogenized with a glass pestle and then soaked in appropriate volume of 80% ethanol and left for about 3 days at room temp away from light. The mixture was then filtered twice through Whatman paper No. 1 with 80% ethanol. The solvent was air-dried and the extract was weighed and suspended in 0.9% sterile saline at concentration of 1 % as a stock suspension.

### Pesticide Preparation

Mitac (a.i: 20% Amitraz; Schering-Plough, USA) was used. Oral amitraz LD<sub>50</sub> for mice is 1600 mg kg<sup>-1</sup>.

### Animals and Administration

Forty eight male Swiss albino mice of 8 weeks old and 22-25 g weight were raised at the experimental animal house of the Faculty of Science, Fayoum University in year 2007. The animals were maintained in controlled environment of temperature, humidity and light. They were fed a commercial mouse chow and tap water. The mice were divided into four groups (12 mice each). The 1<sup>st</sup> was injected with 0.9% sterile saline (control), the 2<sup>nd</sup> had 150 mg propolis/kg (body weight), the 3<sup>rd</sup> had 160mg amitraz/kg by gavage and the 4th group had 160 mg amitraz/kg + 150 mg propolis/kg. These daily treatments lasted for 8 weeks.

### Laboratory Assays

Total and direct bilirubin concentrations were colorimetrically measured (Shimadzu-CL 770 spectrophotometer), whereas alkaline phosphatase (ALP), aspartate amino transferase (AST) and alanine amino transferase (ALT) concentrations were measured using the enzyme-kinetic method (Mert, 1986). These assays were weekly measured.

### **Histopathology**

Eight weeks after the administration of amitraz, necropsies were performed on the mice, resulting in their death immediately after euthanasia using ether. Slices from the liver were fixed in buffered 10% formaldehyde solution. Paraffin blocks were prepared after passing through ethyl alcohol and xylol stages. Sections of 4-5  $\mu\text{m}$  thickness was cut by a microtome and stained with haematoxylin-eosin and examined under a light microscope for histopathology investigation.

### **Immunohistochemistry**

Tissue sections of 4  $\mu\text{m}$  were mounted on Histogrip (Zymed, USA) coated glass slides and air-dried overnight at room temperature. Immunohistochemical staining was performed using an avidin-biotin peroxidase complex. Briefly, samples were treated with 0.6% hydrogen peroxide in methanol for 30 min to block endogenous peroxidase activity. Staining of formalin-fixed tissues requires boiling tissue sections in 10 mM citrate buffer, pH 6.0, (Neomarkers Cat. No. AP-9003) for 20 min which was followed by cooling at room temperature for 20 min. The slides were incubated with normal goat serum (1:10) (Neomarkers, USA) for 10 min and then with mouse monoclonal Ki67 as the proliferation marker (Neomarkers, USA), at dilution of 0.5-1.0  $\mu\text{g mL}^{-1}$  for 60 min at room temperature. The sections were further incubated with biotinylated goat anti-rabbit IgG diluted to 1:500 (Sigma-Aldrich, USA) for 10 min, followed by incubation with peroxidase-conjugated streptavidin diluted to 1:3000 in phosphate-buffered saline for 15 min. The peroxidase reaction was performed using 0.02% 3, 3'-diaminobenzidine tetrahydrochloride (DAB) and 0.01% hydrogen peroxide and counterstaining was performed with hematoxylin for 1 min. In case of negative control, the primary antibody was omitted. The positive stains are brown nuclear stain and the counter stain is haematoxylin.

After identifying at low power (100X), each section was counted manually at the high power (400X) in the representative areas with the highest concentration of stained cells according to the recommendation of Cohen *et al.* (1993). To count the labeling index of Ki67, about 1000 cells/slide were counted in each of five microscopic fields from well-labeled areas to determine the average of Ki67. LI was expressed as a percentage of labeled cells (positive for immunostaining reaction) to the total number of cells counted in each specimen. All identifiable staining was regarded as positive. The results are expressed as mean plus or minus standard deviation (LI = mean $\pm$ SD %).

### **Statistical Analysis**

The statistical significance was computed using one way analysis of variance (ANOVA) by SPSS 11 for Windows<sup>®</sup>.

## **RESULTS**

It was noticeable that after the first week of the experiment, the mice injected with amitraz (160  $\text{mg kg}^{-1}$ ) have generally exhibited marked reduction in their feeding, general weakness and some of them displayed loss of their balance. But those received the propolis or amitraz with propolis displayed healthy and normal activities as in the control group.

Table 1 explains the changes in liver functions (Bilirubin, AST, ALT and ALP) in different groups, where the biochemical analysis in group treated with propolis and amitraz were nearly similar to those of the control groups, while the level concentrations of liver functions was high in the group which was injected with amitraz only.

There were no histological differences observed between mice administered with propolis and control ones which received no propolis (Fig. 1a), so the term control is suitable for both. Examination of liver of the control animals showed that lobules of the liver appeared as polygonal

Table 1: Biochemical parameters measured in serum of treated and untreated groups (mean±SD)

Groups	Parameters					
	Total bilirubin (mg dL <sup>-1</sup> )	Direct bilirubin (mg dL <sup>-1</sup> )	AST (U L <sup>-1</sup> )	ALT (U L <sup>-1</sup> )	ALP (U L <sup>-1</sup> )	Albumin (g dL <sup>-1</sup> )
Control	0.44±0.19	0.22±0.06	41.50±2.45	40.55±6.10	45.45±7.75	4.63±0.23
Propolis	0.41±0.12	0.21±0.04	40.70±3.35	39.60±5.11	47.23±7.99	4.33±0.20
Amitraz	0.75±0.27	0.27±0.11 <sup>a</sup>	70.80±6.23 <sup>a</sup>	120.45±10.21	35.02±5.35	2.04±0.16 <sup>a</sup>
Amitraz±Propolis	0.43±0.20	0.22±0.07	44.90±3.90	45.88±6.23	40.01±5.26 <sup>a</sup>	3.75±0.23

a = Significant (p<0.01)

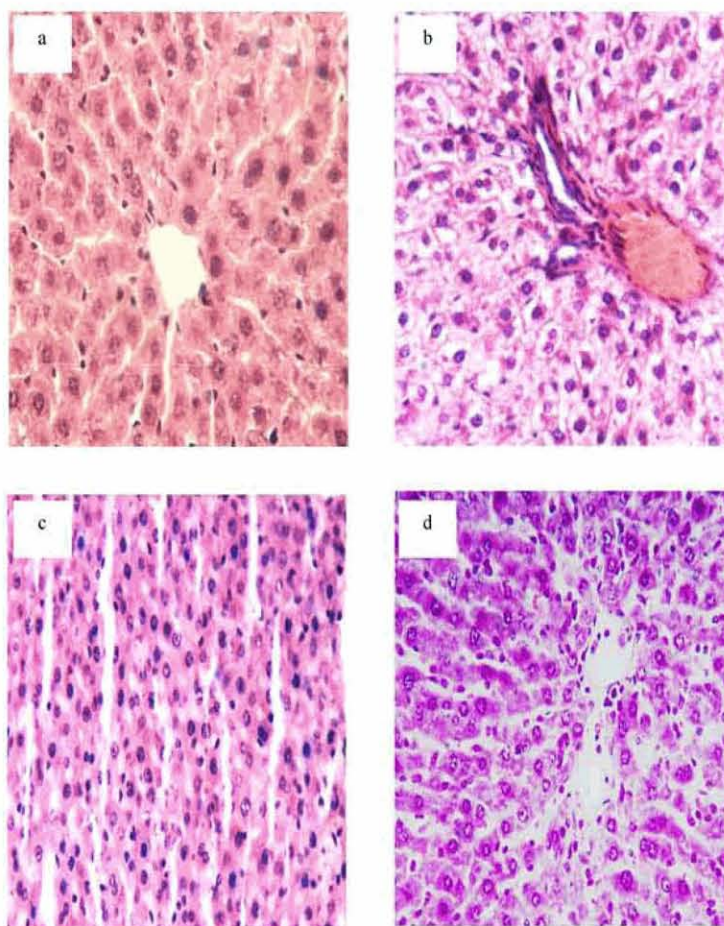


Fig. 1: Light micrograph of control liver (a) lymphocytes infiltration with abnormal liver cells arrangement were in amitraz group (b and c) and the group of amitraz treated with propolis had liver tissue displayed a normal architecture (d). Haematoxylin and Eosin stain (original magnification X 400)

areas. The central vein runs through the center of the lobule. Hepatocytes assemble to long strips of tissue (liver plates), which radiate from the periphery towards the central vein of the lobule. Liver capillaries meander between the liver sinusoids. The sinusoids were narrow blood spaces with irregular boundaries composed essentially of only single layer of fenestrated endothelial cells in addition to large irregularly shaped cells of mononuclear type the *Von kuppfer cells* which are known to be actively phagocytic cells.

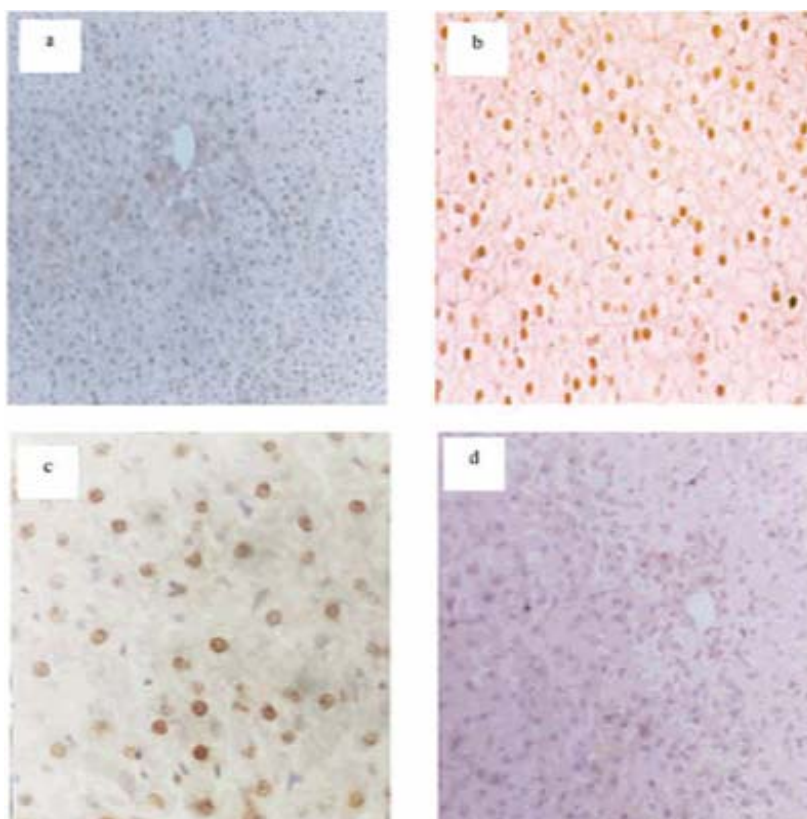


Fig. 2: Immunostaining micrograph of Ki67 expression in different groups (the positively is brown nuclear staining). Control (a) amitraz liver treated group (b and c) and amitraz + propolis treated group (d). Avidin-Biotin peroxidase method (original magnification X 250)

The histopathological changes in amitraz group were more apparently after 3<sup>rd</sup> week of treatment with amitraz, where the normal organized structure of the hepatic lobules was impaired and the characteristic of cord-like arrangement of the normal liver cells was lost, also, the hepatocytes varied in size with shape and the intrahepatic blood vessels were congested with blood (Fig. 1b, c).

Histopathological sections of liver in mice injected with 160 mg kg<sup>-1</sup> amitraz and treated with 150 mg kg<sup>-1</sup> propolis showed somewhat healthy appearance as the liver tissue displayed a normal architecture (Fig. 1d). The hepatocytes restored their morphological feature, their cytoplasm was clearly homogenous. Most hepatocytes nuclei restored their normal appearance and binucleated cells feature, which is considered as an obvious indicator of recovery.

In the present study, the liver sections of control and propolis treated mice immunostained with Ki67 showed very weak positive stained nuclei indicating the mild cell division of some hepatocytes (Fig. 2a). However, sections in liver of mice injected with amitraz only showed strong positive stained nuclei in most of the hepatocytes (Fig. 2b). On the other hand, the hepatocytes of mice treated with amitraz+propolis demonstrated less positive stained nuclei than those of the amitraz treated only (Fig. 2c).

Table 2 explains the changes in liver Ki67 labeling index. Mice injected with amitraz had displayed a highly significant increase, while mice treated with propolis and injected with amitraz illustrated significant increase compared with control mice or those injected with amitraz only.

Table 2: Significance of Ki67 (a proliferation marker) between different groups

Group	Control	Propolis	Amitraz	Propolis +Amitraz
X	10.13	9.985	80.560	18.180
SD	4.32	3.330	7.982	5.451
T-test	-	0.713	18.320	6.340
Significance	NS	*	*	

X =Mean value, SD = Standard deviation, NS=Not significant and \* Significant

## DISCUSSION

Propolis is a resinous substance collected by honeybees and used in hive construction and maintenance. Cumulative evidence suggests that propolis may have anti-inflammatory, antibiotic, antioxidant, antihepatotoxic and antitumor properties. In addition to topical applications, products containing propolis have been used increasingly as dietary supplements (Li *et al.*, 2005).

The rise in both AST and ALT levels ( $p < 0.05$ ) in mice given amitraz was one of the most familiar indicators of hepatocellular damage (Mert, 1986). Also, Al-Qarawi *et al.* (1999) had also reported an increase in serum AST levels in mice given amitraz. However, a significant decrease in ALP level may refer to liver dysfunction. Besides, increasing bilirubin levels indicated diffused harm to the liver.

It could be postulated that the hepatoprotective effect of propolis ethanol extract (PEE) may be, partially, due to its ability to inhibit membrane lipid peroxidation and free radical formation or due to their free radical scavenging ability (Liu *et al.*, 2004). A certain reduction of steatosis degree as well as decreased concentration of liver triglycerides and ALT activity was found in three groups of rats treated with red propolis extract and  $CCl_4$  in relation to those treated with the hepatotoxin (Merino *et al.*, 1996). The present findings indicated that the levels of AST, ALT, bilirubin, ALP and albumin in group injected daily with amitraz (160 mg/kg/bw/day) and treated with propolis (150 mg / kg/ bw / day) were nearlsimilar to those of the control groups.

The histopathological changes displayed by the liver of mice affected by amitraz administration seemed to follow the pattern as the hepatic tissue impairments which appeared in mice treated with amitraz in the form of an inflammatory cell infiltration, swelling of sinusoids, activation of *kupffer* cells, loss of normal hepatic tissue architecture and disappearance of normal organization. Shukla *et al.* (2004) observed damage in hepatocytes and disturbed chord arrangement after toxicant administration and propolis extract (200 mg  $kg^{-1}$ ) was found to be more effective in restoring  $CCl_4$  induced histopathological alterations. So, the histological patterns in amitraz + propolis treatments were as similar as those of the control group where the liver showed somewhat healthy appearance as the liver tissue displayed a normal architecture and hepatocytes restored their morphological feature.

The present study may be the 1<sup>st</sup> attempt, on the combined analysis of hepatoprotective effects of propolis against amitraz toxicity by using proliferation marker (Ki67) with immunohistochemistry technique El-khawaga *et al.* (2003) reported that crude Egyptian propolis has a strong inhibitory activity against tumors. The anti-tumor mechanism may be mediated by preventing oxidative damage and induction of apoptosis. Choi *et al.* (1999) showed that propolis induced apoptosis in a human hepatoma cell line, also, Jin *et al.* (2005) reported that caffeic acid phenyl ester in propolis (CAPE) possesses selective antiproliferative activity toward hepatocarcinoma cell line Hep3B. In this respect, the previous reports explained the antiproliferative activity of propolis which was clear in the present study, since mice injected with amitraz displayed very high proliferation compared to those injected with amitraz and treated with propolis which exhibited low proliferation.

The conclusion of the present study suggests that the honeybee propolis ameliorated the recovery of amitraz hepatotoxicity in mice, where it acts as an antioxidant scavenges free radicals and could restore the normal liver functions and normal histology.

## REFERENCES

- Al-Qarawi, A.A., M.S. Al-Damegh and S.E. Adam, 1999. Effects of amitraz given by different routes on rats. *Vet. Hum. Toxicol.*, 41: 355-357.
- Burdock, G.A., 1998. Review of the biological properties and toxicity of bee propolis. *Food Chem. Toxicol.*, 36: 347-363.
- Choi, Y.H., W.Y., Lee, S.Y., Nam, K.C., Choi and Y.E. Park, 1999. Apoptosis induced by propolis in human hepatocellular carcinoma cell line. *Int. J. Mol. Med.*, 4: 29-32.
- Cohen, M.B., F.M. Waldman and P.R. Carroll, 1993. Comparison of five histopathologic methods to assess cellular proliferation in transitional cell carcinoma of the urinary bladder. *Hum. Pathol.*, 24: 772-778.
- Costa, L.G., J. Gastel and S.D. Murphy, 1991. The formamidine pesticides chlordimeform and amitraz decrease hepatic glutathione content in mice through an interaction with alpha2-adrenoceptors. *J. Toxicol. Environ. Health*, 33: 349-358.
- El-khawaga, O.A., T.A. Salem and M.F. Elshal, 2003. Protective role of Egyptian propolis against tumor in mice. *Clin. Chem. Acta*, 338: 11-16.
- Garnier, R., D. Chataigner and D. Djebbar, 1998. Six human cases of amitraz poisoning. *Hum. Exp. Toxicol.*, 17: 294-294.
- Greenaway, W., J. May, T. Scaysbrook and F.R. Whatley, 1991. Identification by gas chromatography-mass spectrometry of 150 compounds in propolis. *Zeitschrift fur Naturforsch.*, 46: 111-121.
- Grossman, M.R., 1993. Amitraz toxicosis associated with ingestion of an acaricide collar in a dog. *J. Am. Vet. Med. Assoc.*, 203: 55-57.
- Hollingworth, R.M., 1976. Chemistry, biological activity, and uses of formamidine pesticides. *Environ. Health Perspect.*, 14: 57-69.
- Jin, U.H., T.W. Chung, S.K. Kang, S.J. Suh, J.K. Kim, K.H. Chung, Y.H. Gu, I. Suzuki and C.H. Kim, 2005. Caffeic acid phenyl ester in propolis is a strong inhibitor of matrix metalloproteinase-9 and invasion inhibitor: Isolation and identification. *Clin. Chem. Acta*, 362: 57-64.
- Jorens, P.G., E. Zandijk, L. Belmans, P.J.C. Schepens and L.L. Bossaert, 1997. An unusual poisoning with the unusual pesticide amitraz. *Hum. Exp. Toxicol.*, 16: 600-601.
- Li, Y.J., J.L. Lin, C.W. Yang and C.C. Yu, 2005. Acute renal failure induced by a Brazilian variety of propolis. *Am. J. Kidney Dis.*, 46: 125-129.
- Liu, C.F., C.H. Lin, C.C. Lin, Y.H. Lin, C.F. Chen, C.K. Lin and S.C. Lin, 2004. Antioxidative natural product protect against econazole-induced liver injuries. *Toxicology*, 196: 87-93.
- Merino, N., R. González, A. González and D. Remirez, 1996. Histopathological evaluation on the effect of red propolis on liver damage induced by CCl<sub>4</sub> in rats. *Arch. Med. Res.*, 27: 285-289.
- Mert, N., 1986. *Veterinary Clinical Biochemistry*. 1st Edn. Ceylan Matbaacilik, Bursa, Turkey. .
- Moser, V.C. and R.C. MacPhail, 1986. Differential effects of formamidine pesticides on fixed-interval behavior in rats. *Toxicol. Applied Pharm.*, 84: 315-324.
- Schmitt, S. and Z. Buchmann, 2000. UBI APIS IBI SALUS propolis. What is it, propolis anglesko/apiphytotherapy. <http://members2.easyspace.com/apiphyt/a%20>.
- Shukla, S., M. Bhaduria and A. Jadon, 2004. Effect of propolis extract on acute carbon tetrachloride induced hepatotoxicity. *Indian J. Exp. Biol.*, 42: 993-997.
- Wang, D., D.B. Xiang, Y.J. He, Z.P. Li, X.H. Wu, J.H. Mou, H.L. Xiao and Q.H. Zhang, 2005. Effect of caffeic acid phenethyl ester on proliferation and apoptosis of colorectal cancer cells *in vitro*. *World J. Gastroenterol.*, 11: 4008-4012.
- Young, E., 1987. Sensitivity to propolis. *Contact Dermatitis*, 16: 49-50.