

Reconstruction of Chronic Patellar Tendon Ruptures With Extensor Mechanism Allograft

Robert A. Magnussen, MD, Sebastien Lustig, MD, PhD, Guillaume Demey, MD, Hisham Masdar, MD, Ahmed ElGuindy, MD, Elvire Servien, MD, PhD, and Philippe Neyret, MD

Abstract: Chronic patellar tendon ruptures are a difficult clinical problem. Treatment options include repair and augmentation with hamstring tendons and other grafts. We describe a technique of extensor mechanism reconstruction using an allograft consisting of quadriceps tendon, a patellar bone block, patellar tendon, and a tibial bone block. This technique is a salvage procedure indicated only in the most severe cases of chronic rupture after failure of traditional treatment options. An appropriately size-matched allograft is prepared by shaping the anterior 10 mm of the patella into a graft resembling an hourglass. A similarly shaped trough 10 mm in depth is created in the patella of the patient, and a trough matching the tibial bone block is created in the recipient tibia. The graft is placed and secured with sutures in the quadriceps tendon, wires in the patella, and screws and staples in the tibia. Care must be taken to avoid iatrogenic patellar fracture and prominent hardware. Rehabilitation is slow, with gradual restoration of motion. Outcomes have been successful in 14 patients to date with a 4-year mean follow-up. Future work will include improvement of patellar fixation. This technically challenging procedure may restore extensor mechanism function in cases of chronic patellar tendon rupture that have failed other treatment modalities.

Key Words: extensor mechanism, reconstruction, allograft

(*Tech Knee Surg* 2012;11: 34–40)

HISTORICAL PERSPECTIVE

Patellar tendon rupture is a rare but devastating injury that frequently results from significant trauma. Primary repair with or without augmentation often yields good outcomes when tears are addressed promptly after injury. Reconstruction of chronic ruptures of the patella tendon is often difficult because of the proximal retraction of the patella, quadriceps muscle contracture, and poor quality of the remaining patellar tendon tissue.

Various methods have been described for addressing chronic tears of the patellar tendon. If sufficient healthy native patellar tendon remains, primary repair followed by augmentation with hamstring tendon,^{1,2} cerclage wire,³ or polydioxanone tape⁴ can be successful.

If the native tendon is completely lost, reconstruction with allograft tissue is an option. Previous authors have described the use of Achilles tendon allograft in this situation.⁵ Dejour et al^{6–8} described the use of a contralateral extensor mechanism autograft to reconstruct chronic patellar tendon ruptures. The contralateral autograft consisted of a tibial bone

block, the middle third of patellar tendon, a patellar bone block, and the central portion of the quadriceps tendon. Because of the morbidity of contralateral graft harvest, the technique was subsequently modified to use an extensor mechanism allograft of the same shape.⁹ The technique described in this paper represents the evolution of this technique to maximize graft tissue and construct stability to facilitate early motion.

INDICATIONS AND CONTRAINDICATIONS

Reconstruction of a chronic patellar tendon rupture with an extensor mechanism allograft is a salvage procedure. It is indicated in cases with minimal remaining native tendon after the failure of more traditional repair techniques. The key advantage of this reconstructive technique over augmentation and reconstruction with other allografts such as Achilles tendon is its resistance to distention. The shape of the bone cuts and subsequent bone to bone healing allows the construct to resist strong distraction forces while maintaining normal patellar height. Thus, this technique may be successful in severe cases in which other techniques have failed. A variation of this technique has been reported for the treatment of severe patella infera.¹⁰

This procedure is not indicated as a treatment for acute patellar tendon rupture or in cases where significant amounts of native patellar tendon remain. These cases should be treated with primary repair with or without augmentation. In addition, the success of this technique requires stable integration of the allograft tissue with the bone at the tibial tubercle and patella. For this reason, osteonecrosis of the patella or nonunion of a patellar fracture is a contraindication. Finally, because the procedure requires the creation of a trough in the tibial tubercle to accept the graft, the procedure is not indicated in the skeletally immature.

PREOPERATIVE PLANNING

The use of allograft tissue in this procedure requires significant preoperative planning. Primarily, the patients must be informed and they must consent to the fact that allograft tissue will be used. In addition, an appropriate allograft must be obtained. The key concerns include graft safety and sizing. To better ensure the safety of allograft tissue, we recommend careful selection of an approved tissue bank.¹¹ Allograft processing should also be investigated, particularly methods of sterilization that can weaken grafts.¹² Because the length of the allograft patellar tendon determines the patellar height after reconstruction, it is critical that an appropriately sized graft is obtained. The length of the contralateral patellar tendon should be measured on a calibrated lateral radiograph of the contralateral knee and all attempts should be made to obtain an allograft with the same patellar tendon length. Finally, we recommend visual inspection of the quality of the allograft before incision.

From the Department of Orthopaedic Surgery, Hôpital de la Croix Rousse, Centre Albert Trillat, Lyon, France.

The authors have no conflicts of interest.

Address correspondence and reprint requests to Philippe Neyret, MD, Service de Chirurgie Orthopédique, Hôpital de la Croix Rousse, 103 Grande Rue de La Croix Rousse, 69004 Lyon, France. E-mail: philippe.neyret@chu-lyon.fr.

Copyright © 2012 by Lippincott Williams & Wilkins

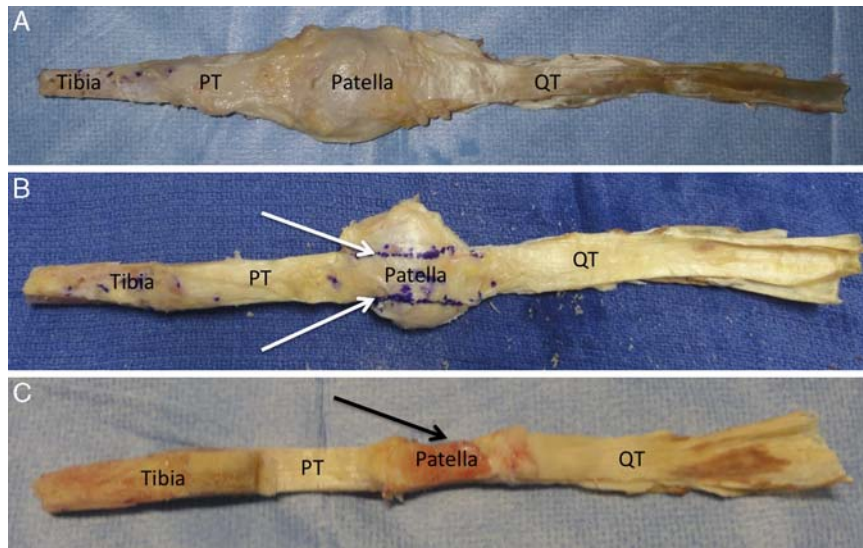


FIGURE 1. A, Anterior view of an extensor mechanism allograft. The tibial bone block, patellar tendon (PT), patella, and quadriceps tendon (QT) are labeled. B, Anterior view of the same allograft with the shape of the patella cut noted (white arrows). C, Posterior view of the allograft after the shaping of the patellar bone block (black arrow).

SURGICAL TECHNIQUE

Graft Preparation

Graft preparation can begin on the back table before patient positioning to save time during the operation. The extensor mechanism allograft typically includes a block of tibial bone of variable size, the entire patellar tendon and patella, and a large portion of the quadriceps tendon (Fig. 1A). The patella

is shaped in a manner to maximize both fixation to the native patella and the area for the patellar and quadriceps tendon attachment. We prefer to cut the patella roughly in the shape of an hourglass in the coronal plane, wider at the top and bottom and narrow in the middle (Fig. 1B). After this cut, a saw is used to remove the articular cartilage and cortical bone from the posterior surface of the patella, resulting in a patellar graft thickness of about 10 mm. The tibial bone block is then

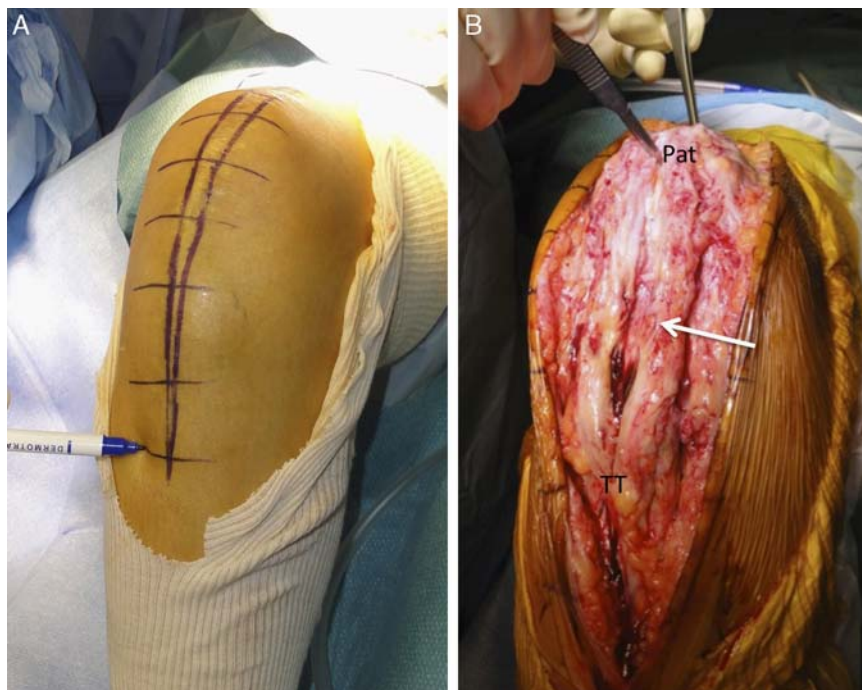

FIGURE 2. A, Anterior view of a right knee demonstrating the incision for extensor mechanism reconstruction. B, The incision has been carried down to the extensor mechanism, identifying the patella (Pat) and the tibial tubercle (TT). The scar tissue and distended remnant of the native patellar tendon has been divided longitudinally (arrow).

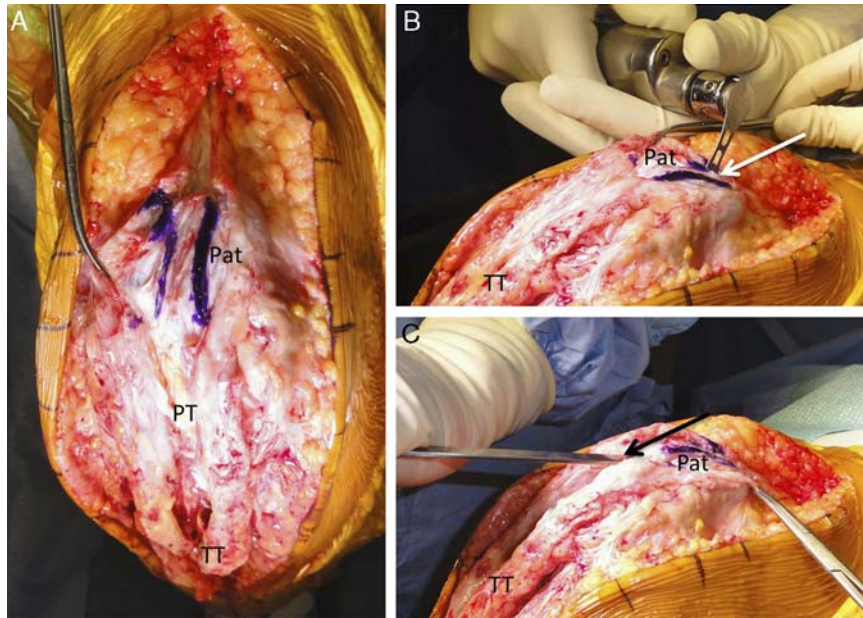


FIGURE 3. A, Anterior view of a right knee with the patella (Pat) marked for creation of the patellar trough. The patellar tendon (PT) and tibial tubercle (TT) are labeled. B, Anteromedial view of the same knee demonstrating preparation of the patellar trough with an oscillating saw (white arrow). C, An osteotome is used to remove the bone from the trough (black arrow).

shaped. Ideally, the bone block should be slightly wider distally than proximally to help prevent superior migration of the graft, but because of the need to preserve the width of the insertion site of the patellar tendon proximally and the limitations of the allograft, this is not always possible (Fig. 1C).

Patient Positioning

While the graft is prepared on the back table, preparation of the patient and knee continues. The patient should be positioned supine with a bump placed under the ipsilateral buttock. An additional bump is placed distally to hold the knee at 90 degrees of flexion. An unsterile tourniquet is applied to the proximal thigh. The limb is prepped and draped with an extremity drape.

Skin Incision and Approach

Approach is through a longitudinal skin incision, beginning 10 cm above the proximal pole of the patella and extending 3 cm below the distal insertion of the patellar tendon. As this procedure is indicated only in severe cases in which prior interventions have failed, scars from prior incision are invariably present and must be considered. The incision must be of sufficient length to allow fixation of the graft in the quadriceps tendon proximally and in the tibia distally (Fig. 2A). The dissection is carried down to the patella and any remaining patellar tendon. The medial and lateral edges of the patella and tibial tubercle are useful landmarks to remain oriented despite abundant scar tissue (Fig. 2B).

Creation of the recipient site for the graft begins by marking its expected position on the patella (Fig. 3A). To match the allograft donor, the recipient site is cut with an oscillating saw roughly in the shape of an hourglass in the coronal plane, wider at the top and bottom and narrow in the middle (Fig. 3B). An osteotome is then used to remove the bone (Fig. 3C), resulting in a trench approximately 10 mm in depth in the same hourglass shape (Fig. 4). The match between the transplant site and the recipient site is then evaluated. It is often necessary to

reshape the graft or trench to obtain a good fit. After preparation of the trench, wires are placed for fixation of the graft

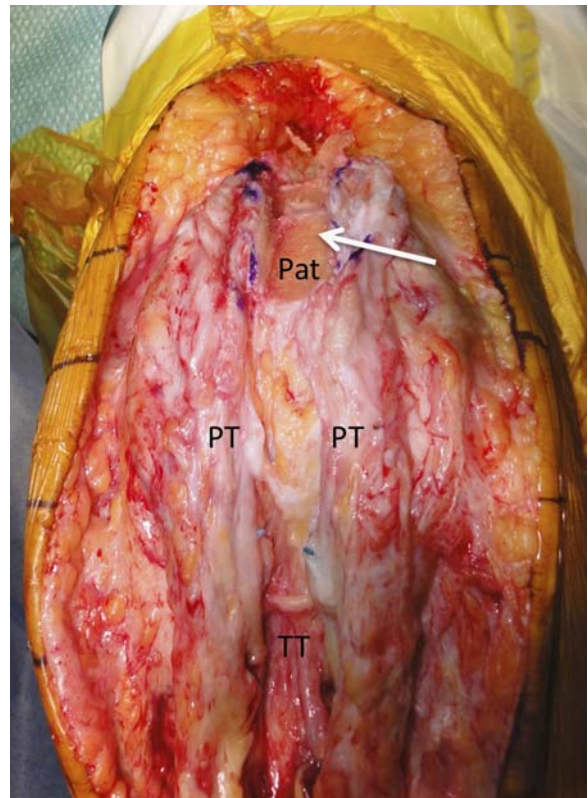


FIGURE 4. Anterior view of a right knee after preparation of the patellar trough (arrow). The patella (Pat), remnant native patellar tendon (PT), and tibia tubercle (TT) are labeled.

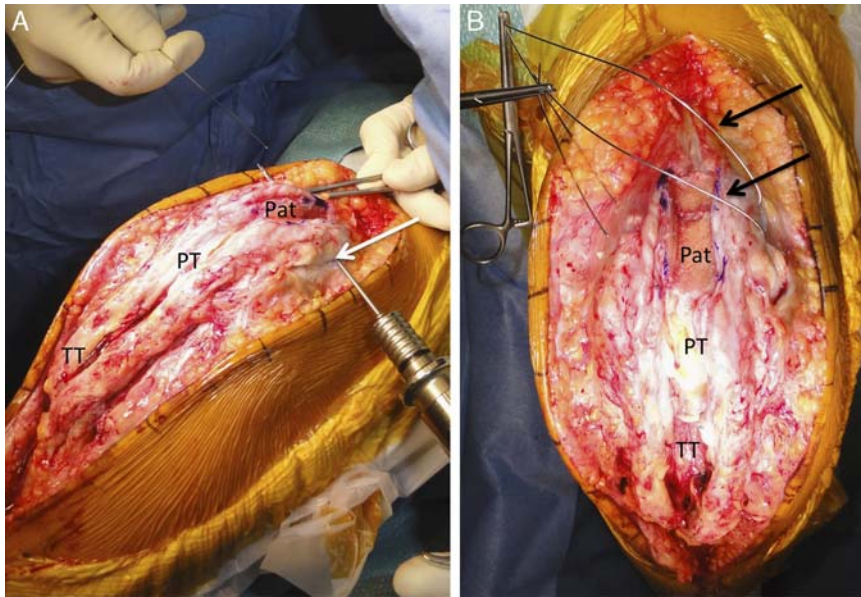


FIGURE 5. A, Anteromedial view of a right knee demonstrating transverse drilling (white arrow) of the patella (Pat) for graft fixation. The residual native patellar tendon (PT) and tibial tubercle (TT) are labeled. B, Anterior view of the same knee after placement of the 2 wires (black arrows) for graft fixation.

in the patella. The wires are placed transversely through the patella deep to the bottom of the trench (Fig. 5).

Attention is then turned to the creation of the recipient site at the tibial tubercle. A trench is created with an oscillating saw to match the shape of the donor block (Fig. 6A). Ideally, the trench is slightly narrower proximally than distally to aid in the

prevention of migration of the graft. An osteotome is then used to remove the bone block (Fig. 6B) and complete the recipient site (Fig. 6C). The match between the graft and the recipient site is again evaluated and adjusted to ensure a good fit.

Fixation of the graft begins proximally by placing the patella bone block into the patellar trench. This should be

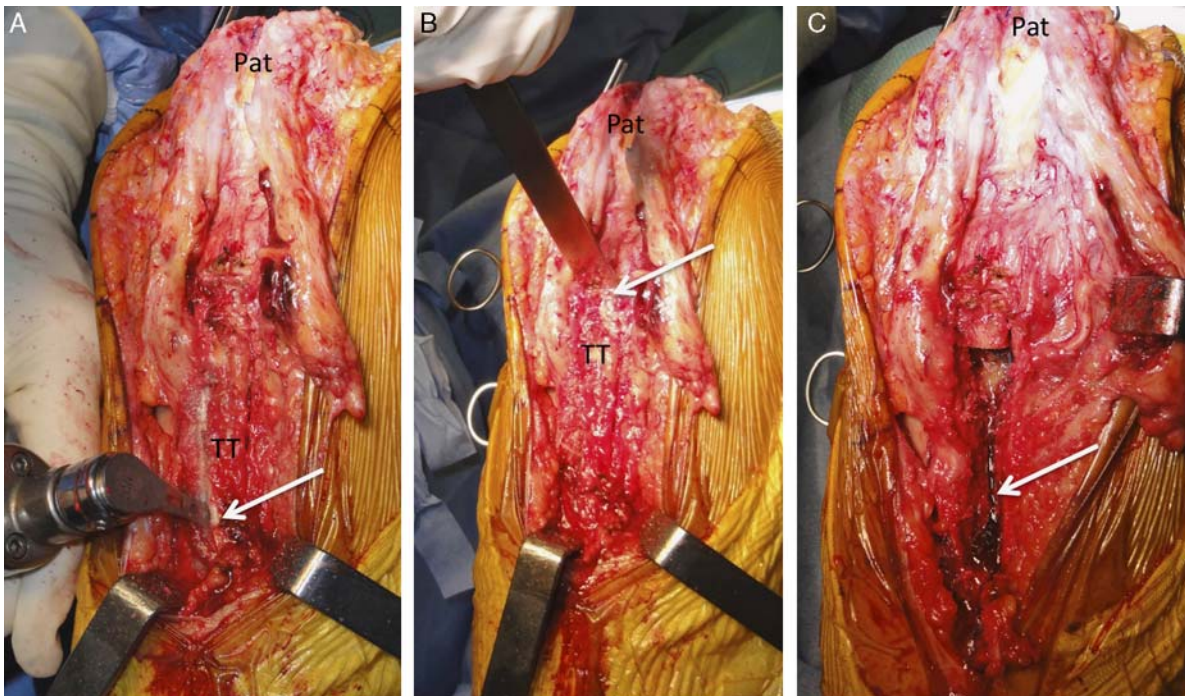


FIGURE 6. A, Anterior view of a right knee during preparation of the tibial trough. An oscillating saw is being used to cut the trough (arrow) in the tibial tubercle (TT). The patellar (Pat) is labeled. B, An osteotome is used to remove the bone block from the tibial trough (arrow). C, Completed tibial bone trough (arrow).

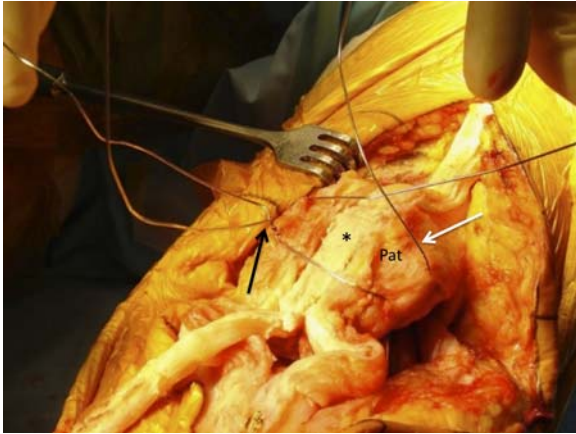


FIGURE 7. Anteromedial view of a right knee during fixation of the patellar bone block (*) into the native patella (Pat). The inferior wire has been tightened (black arrow) and the superior wire is in the course of being placed (white arrow).

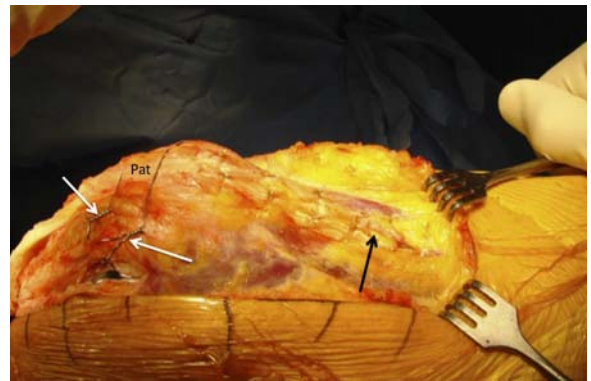


FIGURE 8. Anteromedial view of a right knee after patellar (Pat) bone block fixation with 2 wires (white arrows). The graft quadriceps tendon has been sutured into a longitudinal incision in the native quadriceps tendon (black arrow).

performed without impact to avoid a fracture or injury to the patellar cartilage. The graft is fixed by securing the 2 metal wires over the graft (Fig. 7). The wires are tightened on 1 side by twisting and then cut short and buried. Proximally, the quadriceps tendon portion of the graft is sutured into the longitudinal opening in the center of the quadriceps tendon using number 2 absorbable sutures (Fig. 8).

Tibial fixation begins by placing a wire through the bone block and a screw and washer distal to the tibial trench (Fig. 9). The block is then positioned in the tibial trench with the knee in extension. This step restores the correct patellar height. Fixation is achieved by looping the wire around the distal screw and tightening it. This fixation is supplemented by placing screws or staples through the graft to hold it in position (Fig. 10). Any remaining native patellar tendon can be detached and advanced distally on the tibia, providing additional fixation and soft tissue coverage (Fig. 11).

Closure

The wound is closed over a drain. Absorbable sutures (0 or 2-0) are used for the deep dermal layer and staples or interrupted nylon sutures are used for the skin depending on the skin quality.

RESULTS

The senior author (P.N.) has performed this type of extensor mechanism reconstruction in 14 patients ranging in age from 20 to 64 years, including 9 allograft reconstructions as described here and 5 similar reconstructions using contralateral extensor mechanism autograft. Significant improvements in active knee extension were noted in all cases. At a mean of 4 postoperative years, no patients experienced failure of the graft. In 2 cases, distal “sliding” of the graft in the patella was noted, both without a functional consequence.

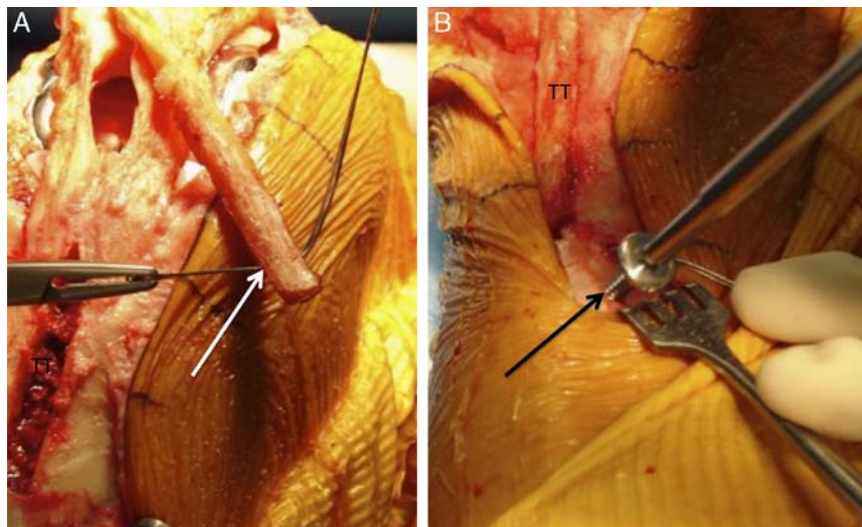


FIGURE 9. A, A wire is passed through a drill hole in the tibial bone block (white arrow) for use in fixation in the tibial tubercle (TT). B, A screw is placed (black arrow) distal to the tibial tubercle for fixation of the graft.

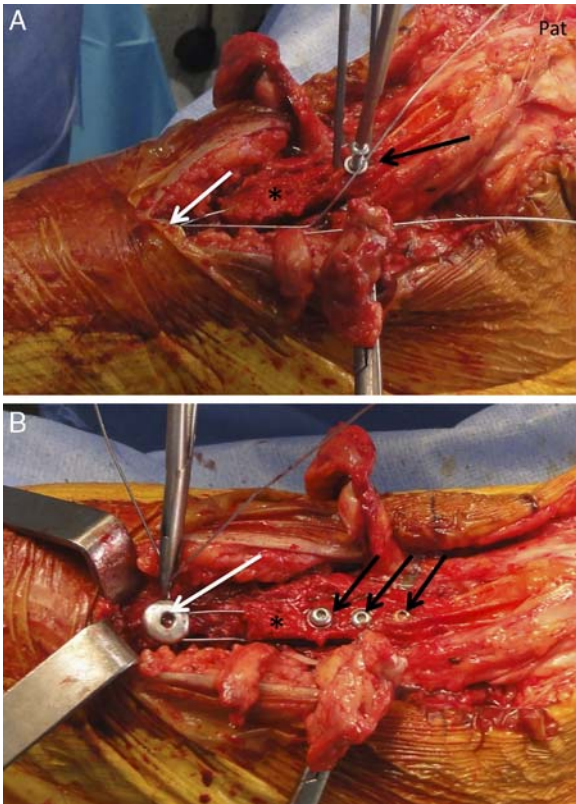


FIGURE 10. A, Anteromedial view of a right knee undergoing fixation of the tibial bone block (*). A screw and washer (white arrow) have been placed distally anchoring the wire that has been placed through the bone block. A screw (black arrow) is placed in the bone block for additional fixation. The patella (Pat) is labeled. B, View after the completion of tibial fixation. The wire (white arrow) is being twisted and buried to avoid prominent hardware. Three screws (black arrows) are present in the bone block.

Complications

Iatrogenic Patellar Fracture

Iatrogenic patellar fracture may occur at several points during this procedure. The highest risk is during preparation of the recipient trough for the graft in the patella. Care must be taken when using the saw and especially the osteotome to avoid fracture. Fracture can also occur when attempting to fit the patellar graft into the trough. One must take ample time to achieve a good match between the graft and the trough. Under no circumstances should a mallet be used to force a poorly sized graft into the trough. Finally, fracture can occur during fixation. Over tightening of wires should be avoided.

Painful Hardware

Retained hardware can become symptomatic and require removal. All wires should be kept low profile and buried in soft tissue when possible to avoid this complication.

Complications Related to Allograft

Disease transmission is an important consideration whenever allograft is used and can be a disastrous complication. Risks of transmission of infectious diseases such as hepatitis B or C or human immunodeficiency virus are extremely low but not zero.^{13,14} An additional concern is a possible

increased risk of local bacterial infection with allograft use.¹⁵ However, several recent studies have demonstrated no increased risk of deep infection when using allografts for anterior cruciate ligament reconstruction in comparison with autografts.^{16,17} To better ensure the safe use of allograft, one must ensure the quality of the tissue bank and allograft handling process.¹¹

Postoperative Management

Patients who undergo extensor mechanism reconstruction progress more slowly with rehabilitation than those undergoing primary repair of a patellar tendon rupture. The limb is braced in 30 degrees of flexion at rest and in full extension during ambulation for 2 months. Motion is gradually restored with the assistance of a physical therapist. Specific limits of range of motion are determined by the intraoperative tension on the reconstruction. Immediate weight bearing is allowed with the knee locked in extension. Anticoagulation is not used because of a risk of bleeding. Because the surgical site is directly subcutaneous, any hematoma formation could lead to skin necrosis and serious complication. Early mobilization and mechanical deep vein thrombosis prophylaxis are used.

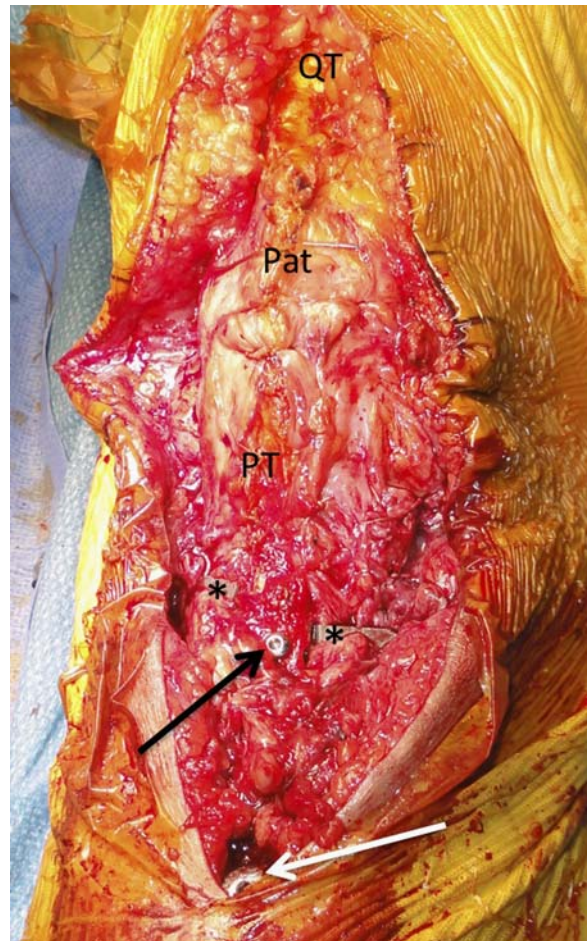


FIGURE 11. Anterior view of a right knee after extensor mechanism allograft reconstruction. The quadriceps tendon (QT), patella (Pat), and reconstruction patellar tendon (PT) are labeled. Two staples (noted with *) used to attach the residual native patellar tendon to the tibia are visible as is one of the screws used to fix the tibial bone block (black arrow) as well as the screw and washed used for fixation distally (white arrow).

Possible Concerns, Future of the Technique

One criticism of this technique is that the surgery itself is technically demanding, with numerous pitfalls and possible complications as outlined above. It must be stressed that this operation is a salvage procedure. It is indicated only for extreme cases in which standard treatment options have failed.

The weakest point in the reconstructed extensor mechanism continues to be the fixation in the patella. As described above, we have witnessed 2 cases in which mild distal slipping of the graft has occurred at its patellar attachment, although this problem has not been clinically significant to date. The inclusion of a relatively large segment of quadriceps tendon in the graft has improved the proximal fixation somewhat, but we continue to work to improve the patellar fixation.

CONCLUSIONS

Allograft reconstruction of the extensor mechanism provides a solution to the difficult clinical situation of a chronic patellar tendon rupture that has failed traditional treatment options including primary repair and augmentation.

REFERENCES

- Ecker ML, Lotke PA, Glazer RM. Late reconstruction of the patellar tendon. *J Bone Joint Surg Am*. 1979;61:884–886.
- Mandelbaum BR, Bartolozzi A, Carney B. A systematic approach to reconstruction of neglected tears of the patellar tendon. A case report. *Clin Orthop Relat Res*. 1988;235:268–271.
- McLaughlin HL, Francis KC. Operative repair of injuries to the quadriceps extensor mechanism. *Am J Surg*. 1956;91:651–653.
- Kasten P, Schewe B, Maurer F, et al. Rupture of the patellar tendon: a review of 68 cases and a retrospective study of 29 ruptures comparing two methods of augmentation. *Arch Orthop Trauma Surg*. 2001;121:578–582.
- Falconiero RP, Pallis MP. Chronic rupture of a patellar tendon: a technique for reconstruction with Achilles allograft. *Arthroscopy*. 1996;12:623–626.
- Dejour H, Denjean S, Neyret P. Treatment of old or recurrent ruptures of the patellar ligament by contralateral autograft. *Rev Chir Orthop Reparatrice Appar Mot*. 1992;78:58–62.
- Dejour H, Denjean S, Neyret P. Treatment of old or recurrent ruptures of the patellar ligament with a contralateral autograft. *French J Orthop*. 1992;6:100–104.
- Neyret P, Donell ST, Carret JP, et al. Patellar ligament rupture treated by contralateral patellar ligament autograft and its application in patients with tibial allografts. *Knee*. 1994;1:158–160.
- ElGuindy A, Lustig S, Servien E, et al. Treatment of chronic disruption of the patellar tendon in osteogenesis imperfecta with allograft reconstruction. *Knee*. 2011;18:121–124.
- Mariani PP. A new surgical procedure for the treatment of patella infera. *Knee Surg Sports Traumatol Arthrosc*. 1994;2:238–241.
- Rihn JA, Harner CD. The use of musculoskeletal allograft tissue in knee surgery. *Arthroscopy*. 2003;19(suppl 1):51–66.
- Rappe M, Horodyski M, Meister K, et al. Nonirradiated versus irradiated Achilles allograft: in vivo failure comparison. *Am J Sports Med*. 2007;35:1653–1658.
- Zou S, Dodd RY, Stramer SL, et al. Probability of viremia with HBV, HCV, HIV, and HTLV among tissue donors in the United States. *N Engl J Med*. 2004;351:751–759.
- Yao F, Seed C, Farrugia A, et al. The risk of HIV, HBV, HCV and HTLV infection among musculoskeletal tissue donors in Australia. *Am J Transplant*. 2007;7:2723–2726.
- Diaz-de-Rada P, Barriga A, Barroso JL, et al. Positive culture in allograft ACL-reconstruction: what to do? *Knee Surg Sports Traumatol Arthrosc*. 2003;11:219–222.
- Barker JU, Drakos MC, Maak TG, et al. Effect of graft selection on the incidence of postoperative infection in anterior cruciate ligament reconstruction. *Am J Sports Med*. 2010;38:281–286.
- Katz LM, Battaglia TC, Patino P, et al. A retrospective comparison of the incidence of bacterial infection following anterior cruciate ligament reconstruction with autograft versus allograft. *Arthroscopy*. 2008;24:1330–1335.