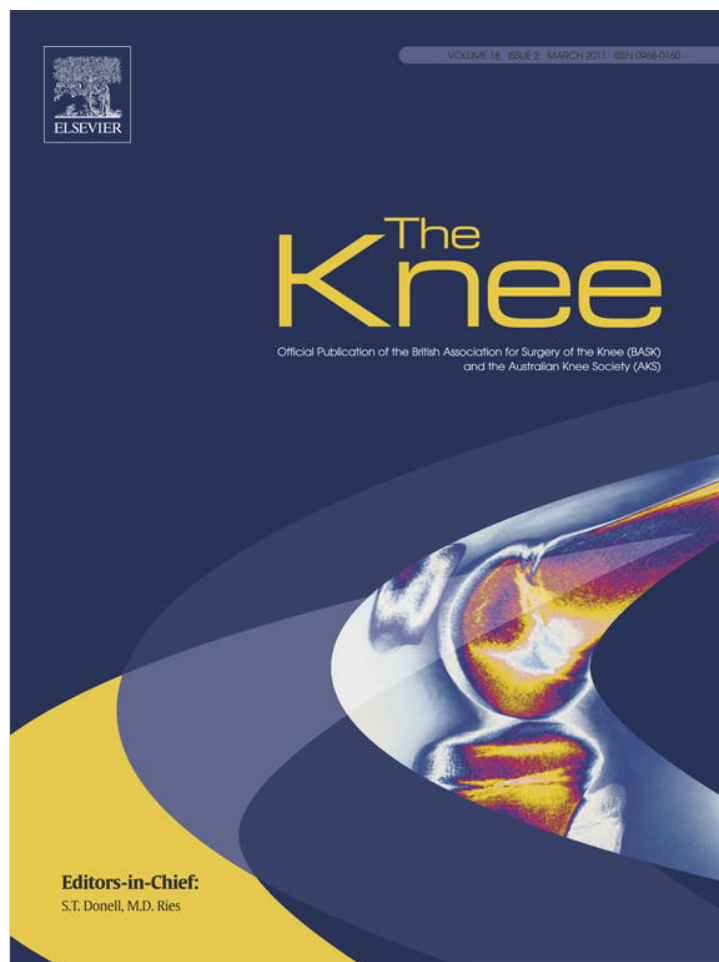


Provided for non-commercial research and education use.  
Not for reproduction, distribution or commercial use.



This article appeared in a journal published by Elsevier. The attached copy is furnished to the author for internal non-commercial research and education use, including for instruction at the authors institution and sharing with colleagues.

Other uses, including reproduction and distribution, or selling or licensing copies, or posting to personal, institutional or third party websites are prohibited.

In most cases authors are permitted to post their version of the article (e.g. in Word or Tex form) to their personal website or institutional repository. Authors requiring further information regarding Elsevier's archiving and manuscript policies are encouraged to visit:

<http://www.elsevier.com/copyright>



Contents lists available at ScienceDirect

## The Knee



## Case Report

## Treatment of chronic disruption of the patellar tendon in Osteogenesis Imperfecta with allograft reconstruction

Ahmed ElGuindy<sup>a,b</sup>, Sebastien Lustig<sup>a,c,\*</sup>, Elvire Servien<sup>a,c</sup>, Camdon Fary<sup>a,d</sup>, Florent Weppe<sup>a</sup>, Guillaume Demey<sup>a</sup>, Philippe Neyret<sup>a,c</sup><sup>a</sup> Service de chirurgie orthopédique, Centre Albert Trillat, Hôpital de la Croix Rousse, 8, rue de Margnolles, 69300 Caluire, Lyon, France<sup>b</sup> Orthopedic Surgery Department, Faculty of Medicine, Fayoum University, Fayoum, Egypt<sup>c</sup> Université Lyon 1, F-69003, Institut National de Recherche sur les Transports et la Sécurité, Bron, F-69675, Laboratoire de Biomécanique et Mécanique des Chocs, UMR\_T 9406, France<sup>d</sup> The Royal Melbourne Hospital, Department of Orthopaedic and Trauma surgery, Parkville, Victoria, Australia

## ARTICLE INFO

## Article history:

Received 4 February 2010

Received in revised form 21 March 2010

Accepted 24 March 2010

## Keywords:

Extensor mechanism

Allograft

Osteogenesis imperfecta

Knee

## ABSTRACT

We present a case of chronic disruption of the patellar tendon in a patient with Osteogenesis Imperfecta. This patient was treated with a customized extensor mechanism allograft. Results were excellent at 5 years follow up. To our knowledge this treatment has not previously been published in this situation. We present this as a reliable treatment option.

© 2010 Elsevier B.V. All rights reserved.

## 1. Introduction

Osteogenesis Imperfecta (OI) is a genetically transmitted mutation affecting type 1 collagen, which is an essential component of bone and tendon. Patients frequently suffer from recurrent bone fractures and to a lesser extent tendon ruptures [1,2]. Disruption of the extensor mechanism is a significant disabling injury which is particularly difficult to treat in these patients. We present a case of chronic disruption of the patellar tendon in a patient with OI. This patient was treated with a customized extensor mechanism allograft.

## 2. Case report

A 27-year old male patient with OI was referred to our hospital in a wheel chair, unable to walk on his left leg.

The patient gave a history of disruption of the extensor mechanism (patellar tendon) which was diagnosed following a fall down stairs 18 months ago. He had been operated on in another hospital with primary repair and augmented with turn down of the quadriceps tendon. This procedure failed to restore the function of his extensor mechanism. His International Knee Documentation Committee 2000 (IKDC 2000) subjective knee score calculated 18 month post injury was 18%.

He had 0° passive extension and 125° of knee flexion (his passive range of motion ROM was 0/0/125). His active extension deficit was 45°, i.e., the patient was not able to actively extend his knee to the neutral. He had a long anteromedial scar from the previous surgery.

Radiological examination (Fig. 1) showed a slightly elevated patella with a Caton–Deschamps index [3] of 1.1 and Blackburne and Peel [4] of 1.05, as compared to 0.7 and 0.6 respectively on his healthy side. Diagnosis of disruption of the extensor mechanism was confirmed by Ultrasonography.

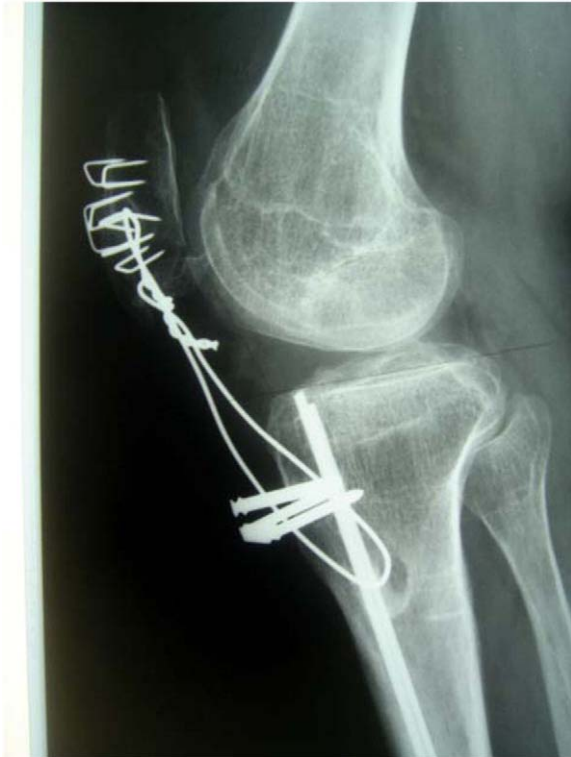He had suffered recurrent fractures, one of which was in the ipsilateral tibia and was fixed with an intramedullary pin. The patient's mother, brother and sister also suffer from OI.

## 2.1. Operative procedure

Under spinal anesthesia a tourniquet was applied to the base of the thigh. Previous anteromedial incision was used and extended to expose the quadriceps tendon, patella, patellar tendon and tibial tuberosity. Material from the failed repair was removed. The extensor mechanism was prepared to receive the allograft (Fig. 2). An incision was made through the quadriceps tendon and a gutter was created on the anterior aspect of the patella. The patellar gutter was along its whole length, 10 mm in width, slightly trapezoidal in shape with the broad end distal. We incised the patellar tendon longitudinally through its length and created another gutter on the anterior aspect of the tibial tuberosity 60 × 10 mm in size. Adhesiolysis of the suprapatellar pouch and gutters were not necessary as the patella descended to the desired position

\* Corresponding author. Tel.: +33 4 72 07 17 94; fax: +33 4 72 07 17 96.

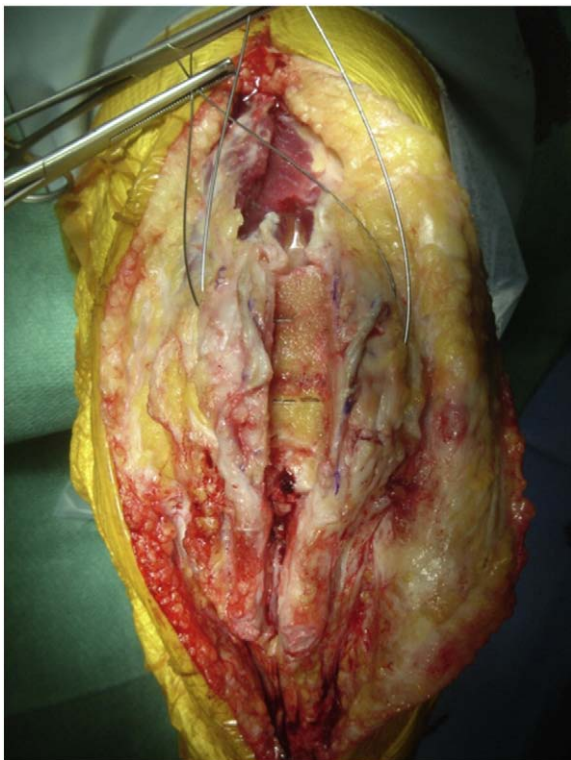E-mail address: sebastien.lustig@chu-lyon.fr (S. Lustig).



**Fig. 1.** Preoperative lateral view of the left knee. Note Patella alta and evidence of previous surgery.

easily. We planned to lower the patella 15 mm by moving the fixation of the allograft within the prepared tibial gutter as required.

A complete extensor mechanism allograft was ordered which consisted of the quadriceps tendon, patella, patellar tendon and a tibial



**Fig. 2.** Intraoperative picture showing the prepared bed in the patella ready to lodge the graft. Note trapezoidal shape of patellar gutter with the wide base inferior.

bone block. Before implanting the allograft was swabbed for bacteriological culture studies and was then left for 20 min in RIFAMPICIN (600 mg/l) solution.

The allograft was prepared so as to fit snugly into the corresponding gutters in the patella and the tibial tuberosity. The tibial end was 60 mm long and 10 mm wide, the patellar tendon was more than 10 mm wide, and the quadriceps tendon was almost 80 mm length. A 2 mm drill bit was used to create a hole in the tibial end. Meticulous care was taken to insure that the prepared allograft corresponded to the gutters created in the patient's patella and tibial tuberosity.

Three horizontal tunnels were created in the patient's patella to accommodate metallic wire fixation. The patellar allograft was impacted into position and the height of the patella was adjusted by varying the position of the tibial allograft component in its gutter. This was checked intra-operatively with image intensifier at 30° of flexion and compared to the pre-operative radiograph of the contralateral side taken with the knee in the same degree of flexion and using the Caton–Deschamps index as a reference. The tibial component was fixed with ORTHOMED® metallic staples and was augmented by a metallic wire passed through the 2 mm hole and fixed on a metallic screw post. The quadriceps tendon was sutured by separate stitches (Fig. 3).

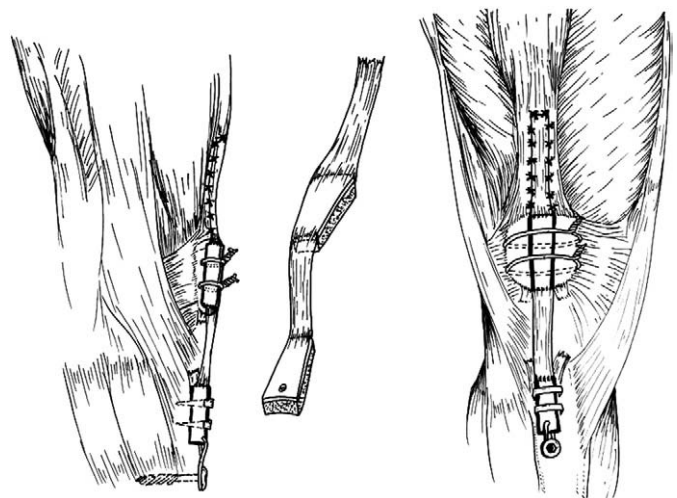
The reconstruction of the extensor mechanism was reinforced by a PDS® band extending from the anterior tibial tuberosity to the quadriceps tendon (Fig. 4).

### 2.2. Post operative care

A splint at 30° of flexion was used at rest for the first month and a removable extension Knee Brace was used during ambulation. The patient was non weight bearing for 2 months. Flexion was gradually increased, reaching 60° in the first month. Flexion was increased to a maximum of 95° in the second month. Afterwards full range of motion was allowed as tolerated. The patient was prescribed cephalosporin antibiotics (1 g t.d.s) until the culture results were negative (2 days).

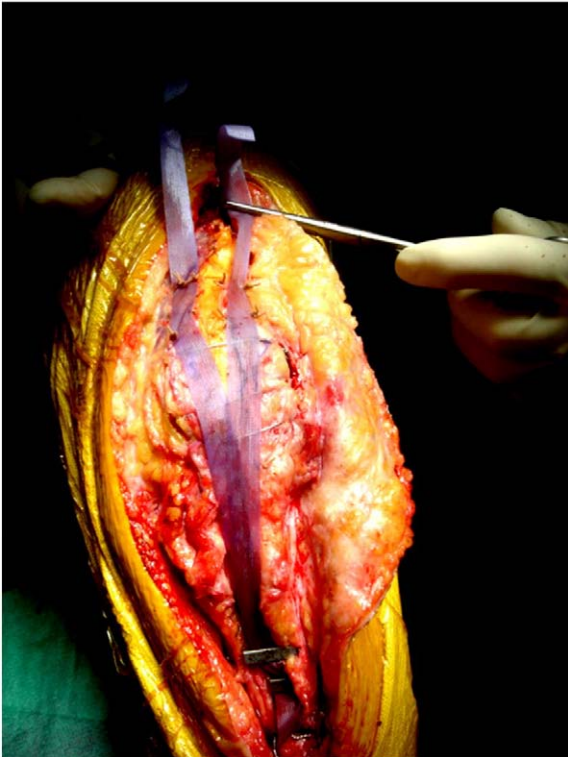The post operative period was uneventful. At 2 months the brace was discarded and weight bearing was restored gradually. The patient reached 120° of flexion at 3 months and by the end of the fifth month his passive range of motion was 5/0/135 with 5° of hyperextension and 135° of flexion. He was able to actively extend his knee to 0° of extension with an active extension deficit of 5° compared to 45° preoperatively.

At 5 years follow up the patient's range of motion was 5/0/135 with no restriction to active extension (Figs. 5 and 6); the patient had



**Fig. 3.** Drawing showing the shape of the prepared graft (note the wedge shaped patellar component) and its application in the prepared gutter (Drawing by Dr Florent Wepppe).



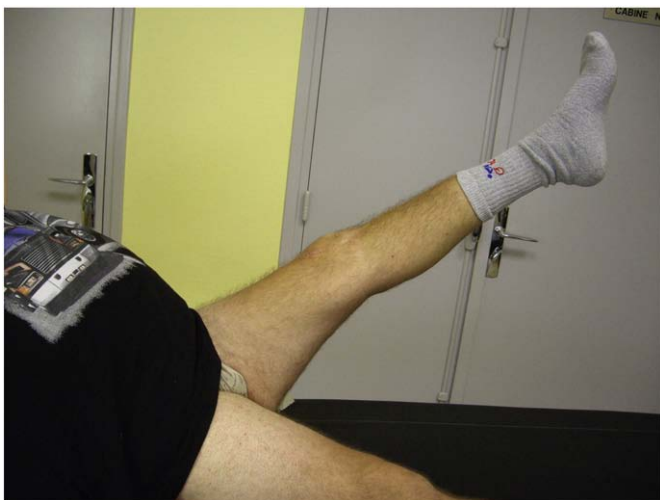

**Fig. 4.** Intraoperative picture showing the PDS® band augmenting the reconstruction.

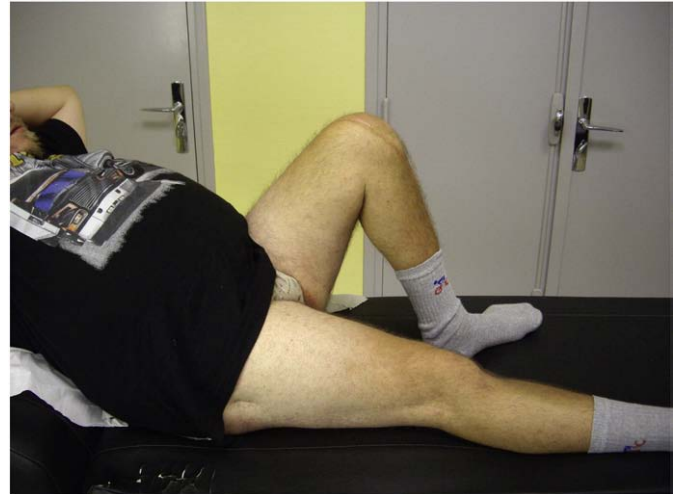no activity restriction. Radiographs (Fig. 7) showed complete incorporation of the bone parts of the allograft. The graft had migrated distally but patellar height was within normal limits, Caton–Deschamps [3] ratio of 0.95 and Blackburne & Peel [4] 0.86. The IKDC subjective knee evaluation score at five years was 58.5%. He described his knee function as optimal compared to pre-operative state where he was unable to perform activities of daily living.

### 3. Discussion

We represent a case of failed primary repair of a ruptured patellar tendon in a patient with OI. In the literature, OI has been associated with tendon rupture, it is commonly bilateral and occurring at osseous insertion sites [5–12].



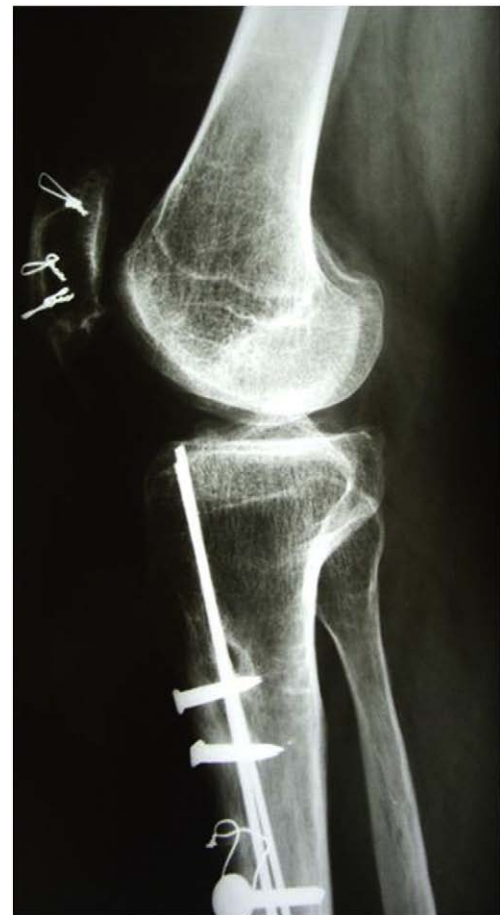**Fig. 5.** Five years postoperative picture showing patient's active full extension.



**Fig. 6.** Five years postoperative picture showing patient's full flexion.

Surgical intervention to repair a patellar tendon rupture is essential to restore the continuity and function of the extensor mechanism [13]. In chronic cases, the patella is retracted proximally and may require extensive surgical release to draw it distally to the appropriate level. Pre-operative assessment of patellar height is essential for proper planning of the procedure.

Various methods of reconstruction of the patellar tendon have been described. If sufficient patellar tendon is left for repair, augmentation



**Fig. 7.** Five year postoperative radiograph showing complete incorporation of the graft, patellar high, and slightly distally displaced graft.

with the semitendinosus or gracilis tendon, as described by Ecker et al. [14] and Mandelbaum et al. [15] may be indicated. If the rupture is several months old or if the tendon is destroyed, hamstring tendons autograft or an allograft can be used. An allograft compared to the weaker hamstring tendons allows earlier more vigorous rehabilitation [16]. Falconiero and Pallis used tendo calcaneal allograft with some success in this situation [17].

We adopted the technique described by Dejour et al. [18,19]. They used a contralateral autograft composed of a block of tibial bone, middle third of patellar ligament, block of patella, and quadriceps tendon. However, in our case, harvesting the contralateral autograft carries the high risk of iatrogenic patellar fracture, which is compounded by the pathology of OI. OI also poses special concern as to the quality of the autografted tendon as it is a generalized disease and is associated with ligamentous laxity [1]. For these factors we chose to use an allograft of the extensor mechanism instead of a contralateral autograft. Apart from this we followed the technique of Dejour et al.

We prefer an extensor mechanism allograft than an Achilles tendon allograft as it has two bony ends which can be fashioned to anchor within the patient's patella and anterior tibial tubercle and also allows for earlier osseous incorporation. This enables more rapid rehabilitation.

The risk of disease transmission is an important consideration and has been thoroughly discussed in literature as a disastrous complication of allograft surgery. A recent study by Katz et al. [20] on ACL reconstructed knees compared infection rates when using autografts and allografts and failed to find a higher rate of deep bacterial infection in ACL reconstructions when allograft tissue was used. To better ensure the safe use of allograft tissue the recommendations of the AAOS on allograft use [21] were followed. We obtained informed consent for allograft tissue use before the procedure, acquired allograft tissue from an approved tissue bank, and closely monitored our patient for signs of infection.

The integration of the allograft was evident on X-rays and it was not necessary to further investigate it with a CT scan examination. The excellent outcome at 5 years postoperatively did not justify exposing the patient to the hazards of radiation.

Our result was considered optimum although the IKDC score at five years was 58.5% because the patient improved from a preoperative score of 18%. He returned to his pre-injury level of activity and was very satisfied. The distal displacement of the graft observed radiologically at five years did not affect the outcome of the procedure, and did not affect the patient's ability to kneel. As a result we now inverse the shape of the patellar graft putting the broad end proximal to prevent this from reoccurring when using an extensor mechanism allograft.

Disruption of the extensor mechanism is a major disabling injury which is complicated to manage. If disruption is associated with the pathology of OI it poses further issues for the orthopaedic surgeon to consider when managing the situation. To our knowledge the use of an extensor mechanism allograft has not been reported in the literature to treat this condition. The combination of the technique proposed by

Dejour et al. [18,19] and the use of an extensor mechanism allograft tissue has enabled us to achieve an optimum result without complications. We recommend this technique in such difficult cases with extensor mechanism disruption.

#### 4. Conflict of Interest

All of the authors haven't received benefits from any commercial organisation related to this study.

#### References

- Misof K, Landis WJ, Klaushofer K, Fratzl P. Collagen from the osteogenesis imperfecta mouse model (oim) shows reduced resistance against tensile stress. *J Clin Invest* 1997;100:40–5.
- Parkinson J, Brass A, Canova G, Brechet Y. The mechanical properties of simulated collagen fibrils. *J Biomech* 1997;30:549–54.
- Caton G, Deschamps G, Chambat P, Lerat JL, Dejour H. [Patella infera. Apropos of 128 cases]. *Rev Chir Orthop* 1982;68:317.
- Blackburne JS, Peel TE. A new method of measuring patellar height. *J Bone Joint Surg Br* 1977;59-B:241–2.
- Imbert P, Loy S. [Rupture in the palm of a flexor tendon in a young man with osteogenesis imperfecta]. *Chir Main* 1999;18:290–4.
- Nigrisoli M, Valdiserri L. [Bilateral laceration of patellar tendon in a case of osteogenesis imperfecta]. *Chir Organi* 1988:259–63.
- Ogilvie-Harris DJ, Khazim R. Tendon and ligament injuries in adults with osteogenesis imperfecta. *J Bone Joint Surg [Br]* 1995;77:155–6.
- Rose PS, Frassica FJ. Atraumatic bilateral patellar tendon rupture. A case report and review of the literature. *J Bone Joint Surg Am* 2001;83-A:1382–6.
- Gallinaro P, Crova M. Lacerazione bilaterale e spontanea del ligamento rotuleo in un caso di osteogenesi imperfetta. *Minerva Oft* 1977;28:627–9.
- McKusick VA. Osteogenesis imperfecta. Heritable disorders of connective tissue. 4. St Louis: C.V. Mosby Co; 1972. p. 405–6.
- Kothari P, Mohan N, Hunter JB, Kerslake R. Case report. Bilateral simultaneous patellar tendon ruptures associated with osteogenesis imperfecta. *Ann R Coll Surg Engl* 1998;80:416–8.
- Dent CM, Graham GP. Osteogenesis imperfecta and Achilles tendon rupture. *Injury* 1991;22:239–40.
- Farrell CM, Scuderi GR, Easley ME. Quadriceps and patellar tendon disruption. In: Insall JN, Scott WN, editors. *Surgery of the Knee*. 2006 ed. New York: Churchill Livingstone; 2006. p. 967–85.
- Ecker ML, Lotke PA, Glazer RM. Late reconstruction of the patellar tendon. *J Bone Joint Surg Am* 1979;61:884–6.
- Mandelbaum BR, Bartolozzi A, Carney B. A systematic approach to reconstruction of neglected tears of the patellar tendon. A case report. *Clin Orthop Relat Res* 1988: 268–71.
- Azar FM. Traumatic Disorders. In: Canale ST, editor. *Campbell's Operative Orthopedics*. 10th ed. Philadelphia: Mosby; 2003. p. 2449–93.
- Falconiero RP, Pallis MP. Chronic rupture of a patellar tendon: a technique for reconstruction with Achilles allograft. *Arthroscopy* 1996;12:623–6.
- Dejour H, Denjean S, Neyret P. Treatment of old or recurrent ruptures of the patellar ligament by contralateral autograft. *Rev Chir Orthop Reparatrice Appar Mot* 1992;78:58–62.
- Neyret P, Donell ST, Carret JP, Dejour H. Patellar ligament rupture treated by contralateral patellar ligament autograft and its application in patients with tibial allografts. *Knee* 1994;1:158–60.
- Katz LM, Battaglia TC, Patino P, Reichmann W, Hunter DJ, Richmond JC. A retrospective comparison of the incidence of bacterial infection following anterior cruciate ligament reconstruction with autograft versus allograft. *Arthroscopy* 2008;24:1330–5.
- Rihn JA, Harner CD. The use of musculoskeletal allograft tissue in knee surgery. *Arthroscopy* 2003;19(Suppl 1):51–66.