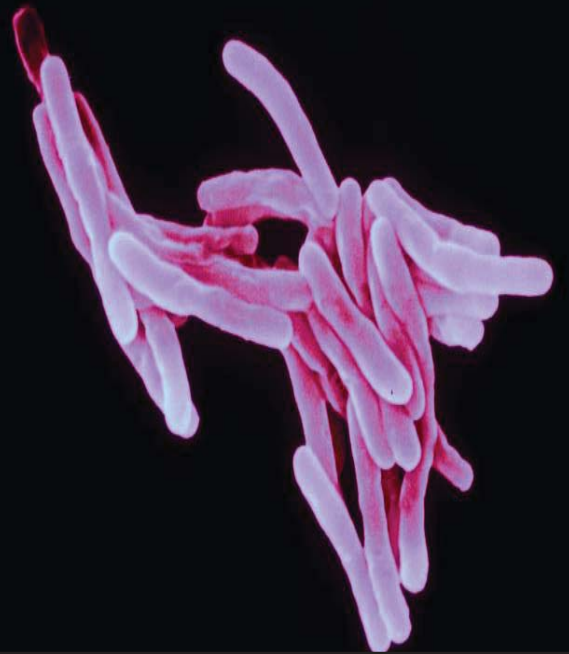



Journal of Drug Metabolism & Toxicology

Open Access

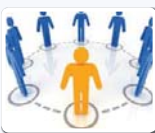



The Journal of Drug Metabolism & Toxicology deals with the biochemical modification of pharmaceutical substances, which includes action of body on the drug and action of drug on the body . It also deals with the study of adverse effects of chemicals on living organisms, usually through specialized enzymatic systems.



The Journal of Drug Metabolism & Toxicology (JDMT) under open access category aims to advance our understanding of the action of drugs and their addictive processes, diagnosis, harmful effects as well as assist in prevention and treatments of addiction. The Journal of Drug Metabolism & Toxicology is an international, peer-reviewed journal publishing an overview of human research on substance abuse which includes the contents geared towards behavioral, psychological, genetic, neuro-biological, and pharmacological aspects.



The Journal of Drug Metabolism & Toxicology explicates the complicated aspects of addiction, psychological and most probably physical addiction despite of its detrimental consequences and increased tolerance, as deemed by the drug addict himself to his individual health, mental state and unmanageable life style. The Journal is promptly available, and is freely accessible globally through internet to share the innovations of the researchers for scholarly advancement in this field.

Journal of Drug Metabolism & Toxicology - Open Access uses online manuscript submission, review and tracking systems for quality and quick review processing. Submit your manuscript at <http://www.editorialmanager.com/pharma/>

Editors & Editorial Board



Dale E Johnson
University of California, USA



Kazim Husain
Ponce School of Medicine, USA



Rais A Ansari
Nova Southeastern University, USA




J Seth Markowitz
University of Florida USA



Ebomoyi William
Chicago State University, USA



William R Ravis
Auburn University USA



Shekhar Anantha
Indiana University Medical Center, USA



R K Srivastava
University of Kansas Medical Center USA



S Richard Myers
University of Louisville School Louisville, USA



Ayman M Noreddin
Hampton University School of Pharmacy USA



N Brustovetsky
Indiana University USA



Shirley M Hogan
University of Mississippi, USA



H Hung-Chang Yao
University of Illinois at Urbana, USA



Vibhudutta Awasthi
University of Oklahoma Health Science Center, USA



Honglian Shi
University of Kansas USA



Xiao-bo Zhong
University of Kansas Medical Center, USA



Sihong Song
University of Florida USA



Stelvio M Bandiera
University of British Columbia, Canada



Jinyong Peng
Dalian Medical University Dalian, China



Wen-Xing Ding
University of Kansas Medical Center, USA



Carol Collins
University of Washington, USA



Oliver Grundmann
University of Florida USA



Phil Ayers
Baptist Health Systems, USA



Maryse Picher
Zintro Inc and CFRx USA



P Krishnamurthy
University of Kansas Medical Center, USA



Santosh Kumar
University of Missouri USA



Udayan Apte
University of Kansas Medical Center, USA



Jason Matthews
University of Toronto USA



Michael Zhou
University of Toronto USA



Nan Mei
National Center for Toxicological Research, USA



Radharaman Ray
U.S. Army Medical Research Institute of Chemical Defence USA



Hariprasad Gali
The University of Oklahoma, USA



Jed N Lampe
University of Kansas Medical Center, USA



Xiang-Qing Yu
DMPK, Toxicology and Pathology, USA



S Narasimha Murthy
Pharmaceutics University of Mississippi School of Pharmacy, USA



Narendra Vais
Pharmacology and Toxicology, USA

OMICS International

15716 Corsa Ave, Suite 110, Westlake, Los Angeles, CA 91362-7354, USA, Email: editor.jdmt@omicsonline.org
Phone: +1-650-268-9744, Fax: +1-650-618-1414, Toll free: +1-800-216-6499

Effect of Nandrolone Decanoate (Anabolic Steroid) on the Liver and Kidney of Male Albino Rats and the Role of Antioxidant (Antox-Silymarin) as Adjuvant Therapy

Amal RS Mohammed¹, Ghada M Al-Galad¹, Amro A Abd-Elgayd¹, Marwa A Mwaheb^{1*} and Hala M Al-hamboly²

¹Department of Forensic Medicine and Clinical Toxicology, Fayoum University, Egypt

²Department of Pathology, Fayoum University, Egypt

*Corresponding author: Marwa A Mwaheb, Department of Forensic Medicine and Clinical Toxicology, Faculty of Medicine, Fayoum University, Egypt, Tel: 0201006267354; E-mail: marwa.mwaheb@yahoo.com

Received date: January 3, 2017; Accepted date: January 25, 2017; Published date: February 1, 2017

Copyright: © 2017 Mwaheb MA, et al. This is an open-access article distributed under the terms of the Creative Commons Attribution License, which permits unrestricted use, distribution, and reproduction in any medium, provided the original author and source are credited.

Abstract

Background and objective: The present study is determining the effect of Nandrolone Decanoate (ND) administration on the liver and kidney of white male albino rats. In addition, study the possible protective effect of administration of Antox and Silymarin on ND.

Methods: The sample consisted of 110 male albino rats that divided into eleven groups treated by Nandrolone Decanoate at a dose of 7.93 mg/kg and 11.9 mg/kg then treated by Silymarin or Antox or both for 8 weeks. The variations in the body weight and weight of liver & kidney organs of rats are determined in all different groups in addition to the variation in liver enzymes (ALT-AST), bilirubin level, kidney function tests: Creatinine and blood urea level among different study groups are measured. The present study represents the hepatic and renal histological changes observed among the different groups.

Results: The highest increase in liver weight the group was treated by ND low dose while the least value of liver weight noted at group is treated by ND high dose. The combination of Silymarin and Antox with ND at high and low dose showed the best results of liver weight. The highest increase in kidney weight showed at ND high dose group while the best result in reduce the kidney weight showed in rats treated by ND low dose with Antox. The highest increase of liver enzymes showed among ND high dose group while the more decrease in liver enzymes showed in groups treated with the combination of Silymarin and Antox with ND at low and high dose. The highest value showed in the group treated by ND high dose while the more decrease in kidney function tests showed in groups treated by the combination of Silymarin and Antox with ND at low and high dose.

Conclusion: The combination of Silymarin and Antox with ND showed the best improvement in liver and renal tissue changes, these means synergistic action to protect the hepato-renal cells against harmful effect of ND by their antioxidant and free radical scavenging activities.

Keywords: Antioxidant; Nandrolone Decanoate; Silmarin; Antox; Liver; Kidney

Introduction

Anabolic Androgenic Steroids (AAS) are synthetic compounds which are the derivatives of testosterone. The androgenic effects of these hormones can be generally considered as those associated with masculinization and the anabolic effects as those associated with protein building in skeletal muscle and bone [1].

Anabolic androgenic steroids have established their benefit in treating various types of anaemia, osteoporosis, androgen replacement therapy, muscle-wasting conditions, cachexia caused by various cancers, and HIV infection. Long-standing hypogonadism in adult males is associated with reduced bone reconstruct and decreased bone formation. In treating muscle-wasting disorders with AAS, none of AAS preparations has proved to be superior to another [2]. Recently, AAS has been studied for male andropause replacement therapy, but

more studies are required before AAS can be used broadly for improving the quality of life of ageing males [3].

Among a vast number of flourishing AAS drugs, the 19-nor-testosterone derivative, Nandrolone Decanoate (ND), is one of the most commonly abused AAS compound in the world [4]. Thus, ND is the drug used in the experimental animal studies upon which this thesis is based. Nandrolone is frequently used to handle many clinical symptoms and diseases, such as osteoporosis, HIV-associated muscle wasting [5]. However, despite such therapeutic beneficial potentials, chronic and unregulated use of Nandrolone result in undesirable outcomes, including hepatic toxicity, alternation of thyroid function, cardiovascular toxicities [6].

Silymarin, an antioxidant flavonoid complex derived from the herb milk thistle (*Silybum marianum*) has long been used in the treatment of liver diseases. This property seems to be due to its ability to scavenge free radicals [7].

Antox is an antioxidant drug composed of selenium, vitamin A acetate, ascorbic acid and vitamin E. Antox was used in therapy of various liver diseases and kidney injury [8].

The aim of the present study is to determine the effect of Nandrolone Decanoate administration on the liver and kidney of white male albino rats. In addition, study the possible protective effect of administration of Antox and Silymarin on Nandrolone Decanoate-induced changes on liver and kidney enzymes and histopathology.

Materials and Methods

The present study was conducted to evaluate the effect of the administration of Nandrolone Decanoate (an anabolic steroid) on the liver and kidney of white male Albino rats. The entire experimental protocol that involved the use of animals was approved by the Ethics Committee for Animal Research and was conducted in with conformity the institutional and national guidelines for the care and use of animals.

Nandrolone Decanoate has the trade name (Deca-Durabolin) from an Organon company in the form of ampoule 25 mg.

Silymarin obtained from Mepaco company in the form of tablets each tablet contains 140 mg.

Antox obtained from Sedico company in the form of tablets each tablet contain 185 mg.

Animals

The sample consisted of 110 male 7 week old albino rats that were provided by Institute of Ophthalmology, Giza. They were given the ordinary rodent diet and tap water separately housed in cages (one rat per cage). The animals were randomly divided into 8 groups; each group contains 10 rats as follows:

Group 1: Negative control group. Animals untreated and served as negative control.

Group 2: Positive control group. Animals treated by Silymarin orally at a dose of 20 mg/kg BW/day for 8 weeks.

Group 3: Positive control group. Animals treated by Antox orally at a dose of 51.6 mg/kg BW/day for 8 weeks.

Group 4: Nandrolone Decanoate (ND) treated group by 1/75 of the LD50. The rats treated by Nandrolone Decanoate at a dose of 7.93 mg/kg BW (1/75 of the LD50) given by intraperitoneal injection once per week for 8 weeks.

Group 5: Nandrolone Decanoate (ND) treated group by 1/50 of the LD50. The rats treated by Nandrolone Decanoate at a dose of 11.9 mg/kg BW (1/50 of the LD50) given by intraperitoneal injection once per week for 8 weeks.

Group 6: Nandrolone Decanoate (ND) plus Silymarin treated groups:

(A) The rats treated by Silymarin (20 mg/kg BW/day) orally for 8 weeks, Nandrolone Decanoate (7.93 mg/kg BW) given by intraperitoneal injection once per week for 8 weeks.

(B) The rats treated by Silymarin (20 mg/kg BW/day) orally for 8 weeks, Nandrolone Decanoate (11.9 mg/kg BW) given by intraperitoneal injection once per week for 8 weeks.

Group 7: Nandrolone Decanoate (ND) plus Antox treated groups:

(A) The rats treated by Antox (51.6 mg/kg BW/day) orally for 8 weeks, Nandrolone Decanoate (7.93 mg/kg BW) given by intraperitoneal injection once per week for 8 weeks.

(B) The rats treated by Antox (51.6 mg/kg BW/day) orally for 8 weeks, Nandrolone Decanoate (11.9 mg/kg BW) given by intraperitoneal injection once per week for 8 weeks.

Group 8: Nandrolone Decanoate (ND) plus Antox-Silymarin treated groups:

(A) The rats treated by Silymarin (20 mg/kg BW/day) orally for 8 weeks, Antox (51.6 mg/kg BW/day) orally for 8 weeks and Nandrolone Decanoate (7.93 mg/kg BW) given by intraperitoneal injection once per week for 8 weeks.

(B) The rats treated by Silymarin (20 mg/kg BW/day) orally for 8 weeks, Antox (51.6 mg/kg BW) orally for 8 weeks and Nandrolone Decanoate (11.9 mg/kg BW) given by intraperitoneal injection once per week for 8 weeks.

A drug used in treatment of rats

The groups received intraperitoneal injections of Nandrolone Decanoate has trade name (Deca Durabolin) in the form of ampoule 25 mg.

The groups received Silymarin in the form of tablets each tablet contain 140 mg.

The groups received Antox composed of vitamin A (0.554 mg), vitamin C (100 mg), vitamin E (30 mg), and selenium (50 µg), in the form of tablets each tablet contains 185 mg.

Tissue harvesting procedures

At the end of the experiment, the animals sacrificed by cervical decapitation and laparotomy were carried out to remove the tissues (kidney& liver) that were weighted and stored in a formalin solution.

Sample of 0.5 cm³ of the organs (liver and kidney) were removed and fixed in 10% neutral formalin for 24 hr followed by washing, dehydration in ascending grades of alcohol, clearing in xylene and embedding in hard paraffin. Samples were then serially sectioned a thickness of 5-6 µ, mounted on albuminized slides and left for 24 hr at 37°C to dry and to avoid detachment of sections during subsequent steps of staining. The tissue sections were stained with Hematoxylin and Eosin stain and then examined under the light microscope. The histopathological examination of liver and kidney will be carried out to determine any associated changes and compare between groups. The liver tissue sections were also stained with special stain (Masson's trichrome stain) to showing the fibrosis of liver tissue.

Biochemical analysis

Blood samples were collected, then centrifuge. The plasma was stored in eppendorf tubes and frozen at -80°C to subsequent analysis.

The determination of the plasma concentration of AST (aspartate aminotransferase) Normal 21-23, ALT (alanine aminotransferase) Normal 14-18, Total Bilirubin (Normal 0.6-0.8), Urea serum level (Normal 18-21) and creatinine serum level (Normal 0.74-0.92) were measured by standard methods adapted for a RA 1000 analyser (Technicon, USA).

Statistical analysis

Data was collected and coded to facilitate data manipulation and double entered into Microsoft Access and data analysis was performed using SPSS software version 18 under windows 7.

Simple descriptive analysis in the form of numbers and percentages for qualitative data, and arithmetic means as central tendency measurement, standard deviations a measure of dispersion for quantitative parametric data, and inferential statistic test:

For quantitative parametric data: One way ANOVA test in comparing more than two independent groups of quantitative data.

For quantitative non parametric data: Non Paired variables: Kruskal Wallis test used in comparing more than two independent groups. Paired variables: Freidman test used in comparing more than two groups of dependant data.

For qualitative data: Chi square test to compare two of more than two qualitative groups.

The level $P \leq 0.05$ was considered the cut-off value for significance.

Results

The variations in the body weight of rats are determined at every week up to 8 weeks. According Figure 1, the maximum weight noted in rats treated by ND at the high dose at different interval times, ND get the highest weight gain compared to the rats which treated by Silymarin or Antox. Silymarin reduce the weight gain of rat which treated by ND at low and high dose. The effect of Antox gets the same behaviour of Silymarin, which reduce the weight gain. The combination of Silymarin and Antox reduce the weight gain of rats compared to the rate which treated by Silymarin or Antox only.

The relations between the weight of organs (liver and kidney) are noted at different time intervals of the experiment according to the types of treatments groups of the rats.

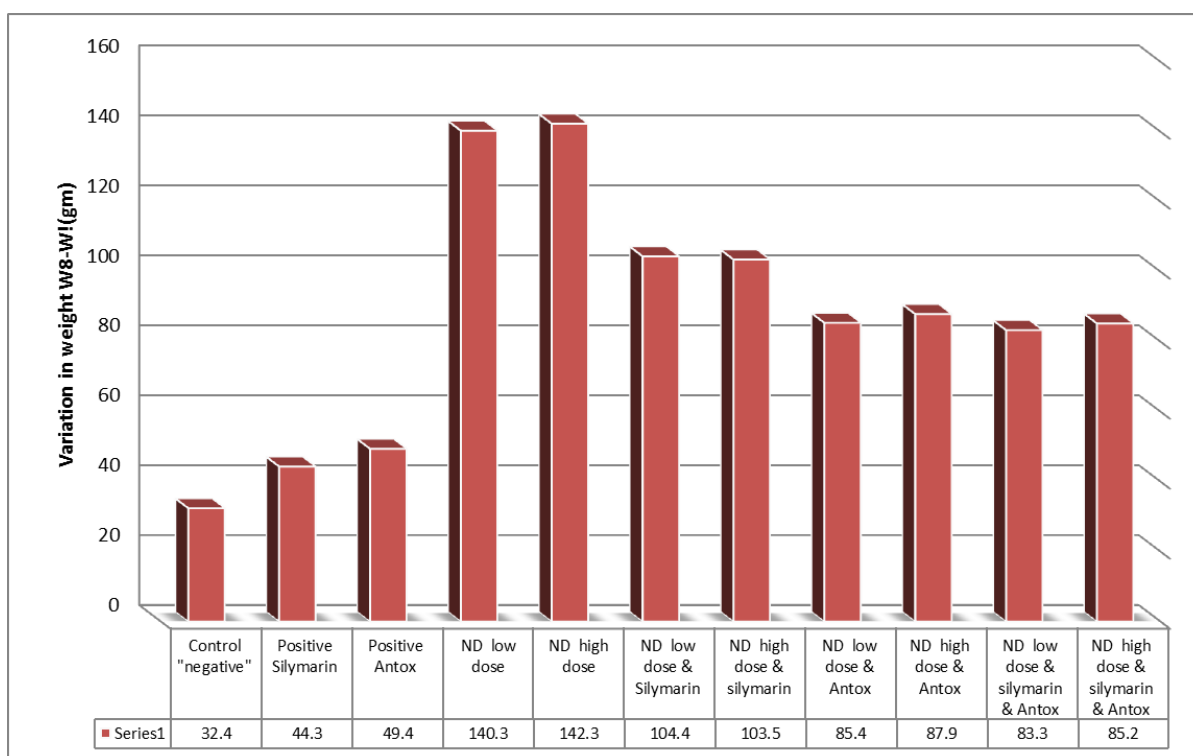


Figure 1: The variation in weight of rats at different groups compared to the initial weigh.

According to the Figure 2, weight of livers get the higher value in group is treated by ND low dose, while the lower value of liver weight recorded at group is treated by ND high dose.

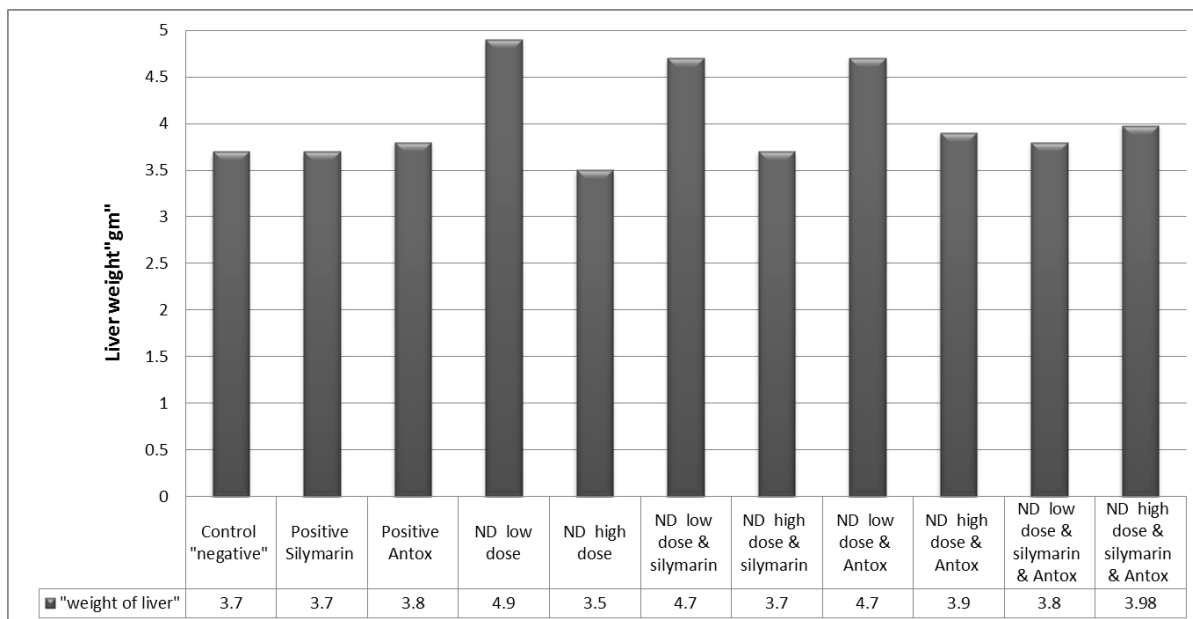


Figure 2: Shows the variation in liver weight of rats according to types of treatment groups of the rats.

The increasing weight of liver in the ND low dose group is decreasing in presence of Silymarin or Antox only or in the presence of both. This behaviour is changed in presence of ND high dose which cause decreases in liver weight due to the damage effect followed by increases in weight of liver in the presence of Silymarin or Antox whose reduce this damage.

According to the Figures 3 and 4, the variation in kidney weight gets different trend compared with liver weight. The high value of kidney weight recorded at ND high dose, while the lower value of kidney weight is recording at control group, Silymarin and Antox groups with slightly change.

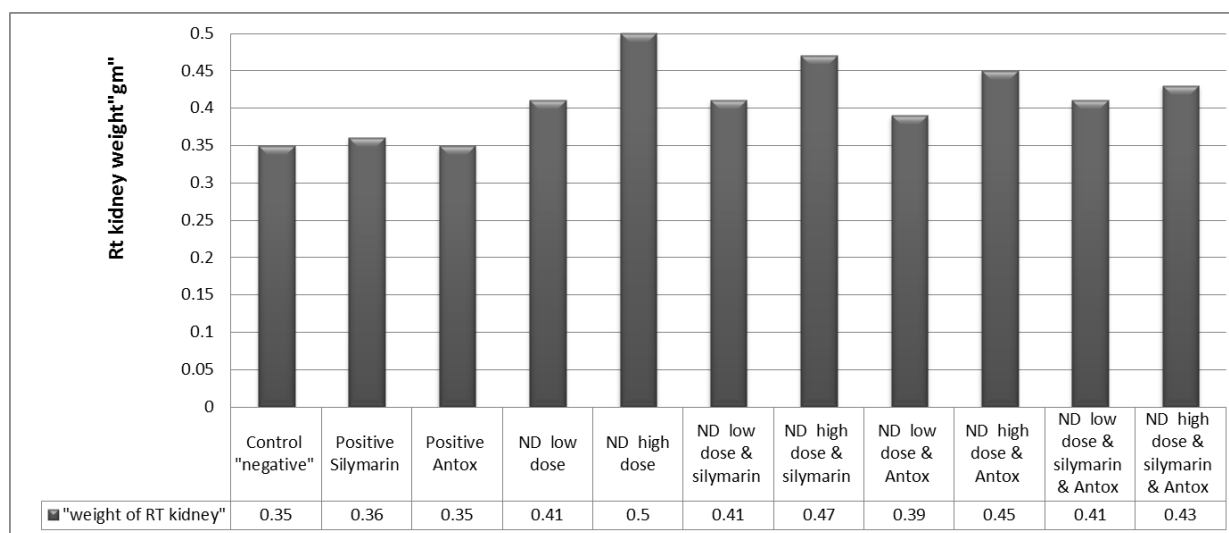


Figure 3: Shows the variation in right kidney weight of rats according to types of treatment groups of the rats.

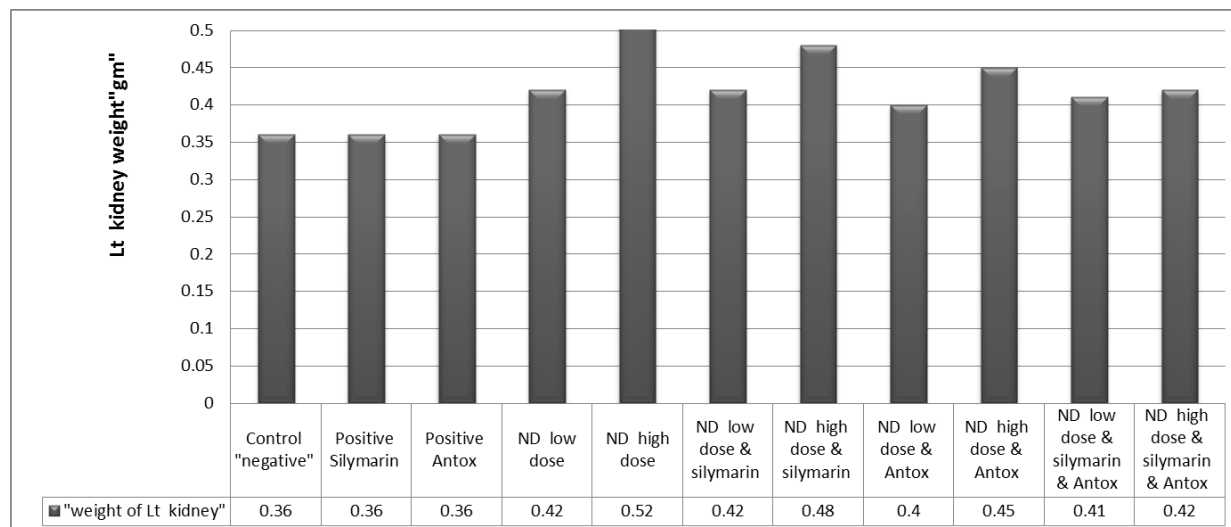


Figure 4: Shows the variation in lift kidney weight of rats according to types of treatment groups of the rats.

Silymarin reduce the kidney weight of rat which treated by ND high dose. Antox reduce the kidney weight at ND low and high dose. The combination of Silymarin and Antox reduce the kidney weight of rats compared to the rat, which treated by Silymarin or Antox only.

The variation in liver enzymes (ALT-AST) in IU/L and bilirubin level by mg/dl among different study groups showed in the following figures.

The Figures 5-7; illustrate that there is high increase of liver enzymes (ALT, and AST) and bilirubin level among ND high dose group, which indicate negative impact of this drug on liver function. The increasing in liver enzymes are decreases in groups treated by ND with Silymarin and more decrease in groups treated by ND with Silymarin and Antox.

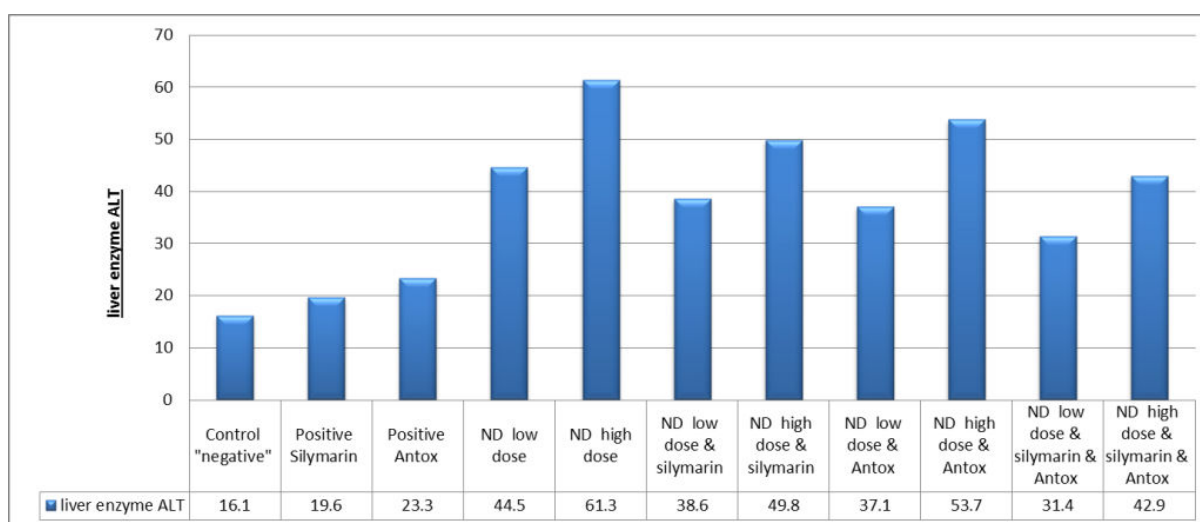


Figure 5: Shows the variation in liver enzyme (ALT) according to types of treatment groups of the rats.

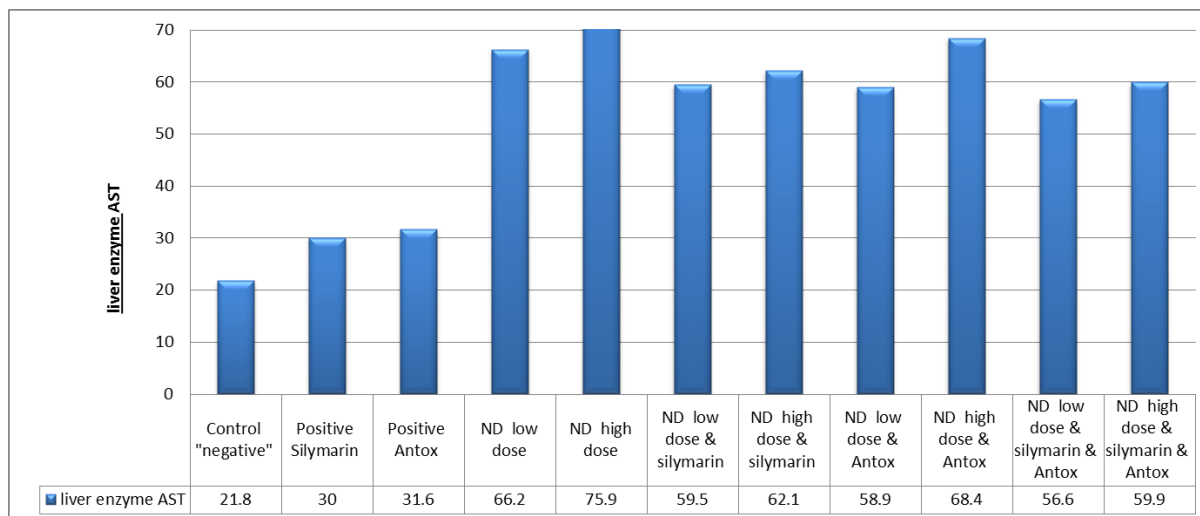


Figure 6: Shows the variation in liver enzyme (AST) according to types of treatment groups of the rats.

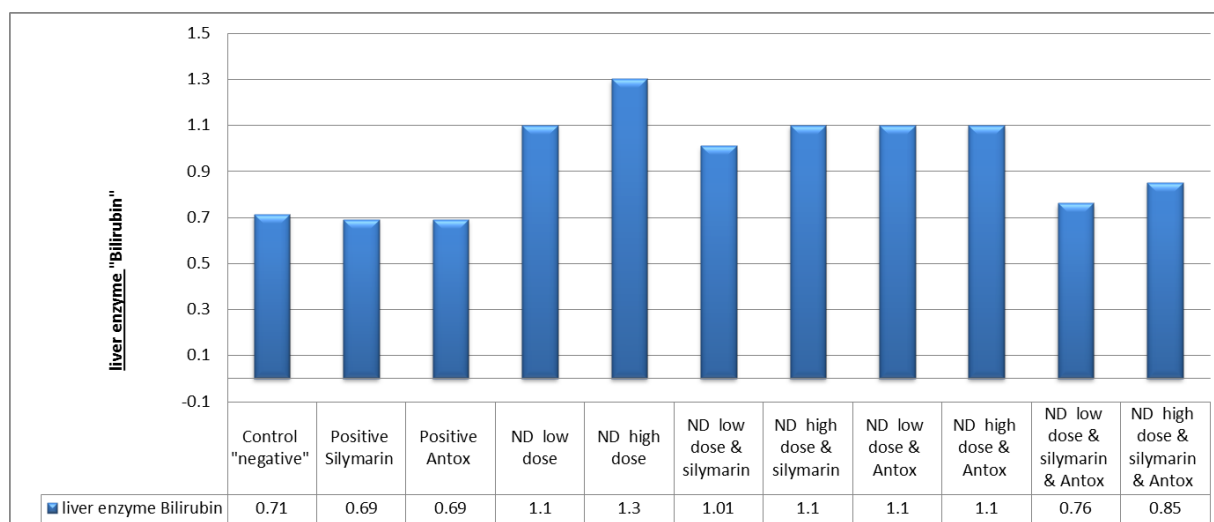


Figure 7: Shows the variation in bilirubin level according to types of treatment groups of the rats.

The variation in kidney function tests creatinine and blood urea level by mg/dl among different study groups showed the following figures.

The Figures 8 and 9 illustrates that there is high increase of urea, and creatinine level among ND high dose groups, which indicate

negative impact of this drug on kidney function. This high kidney function tests decrease in groups treated by ND with Antox and more decrease in groups treated by ND with Silymarin and Antox.

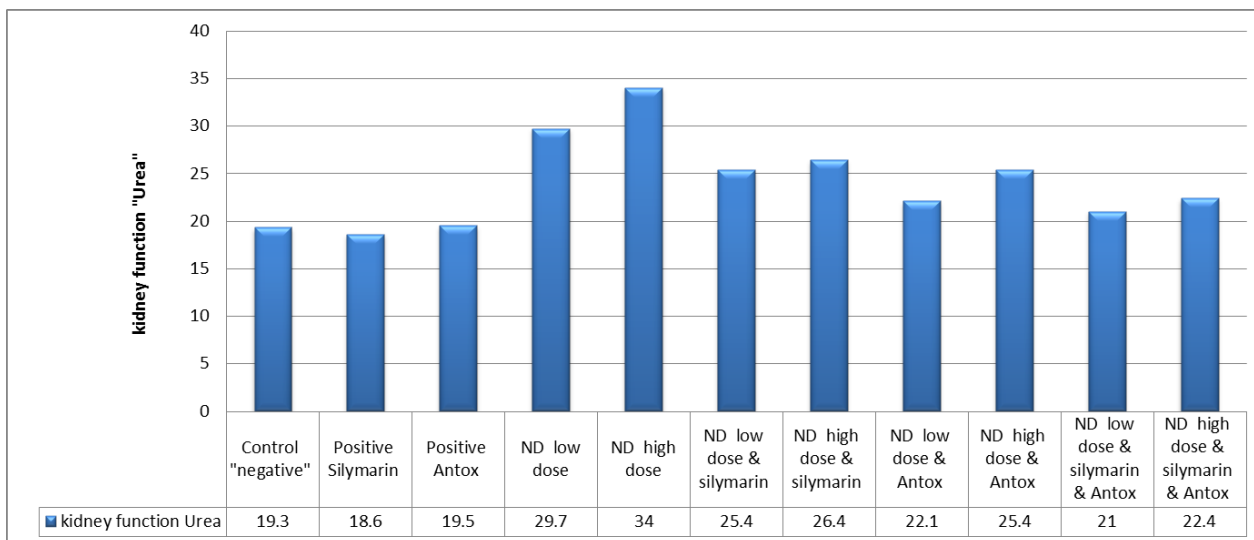


Figure 8: Shows the variation in urea blood level according to types of treatment.

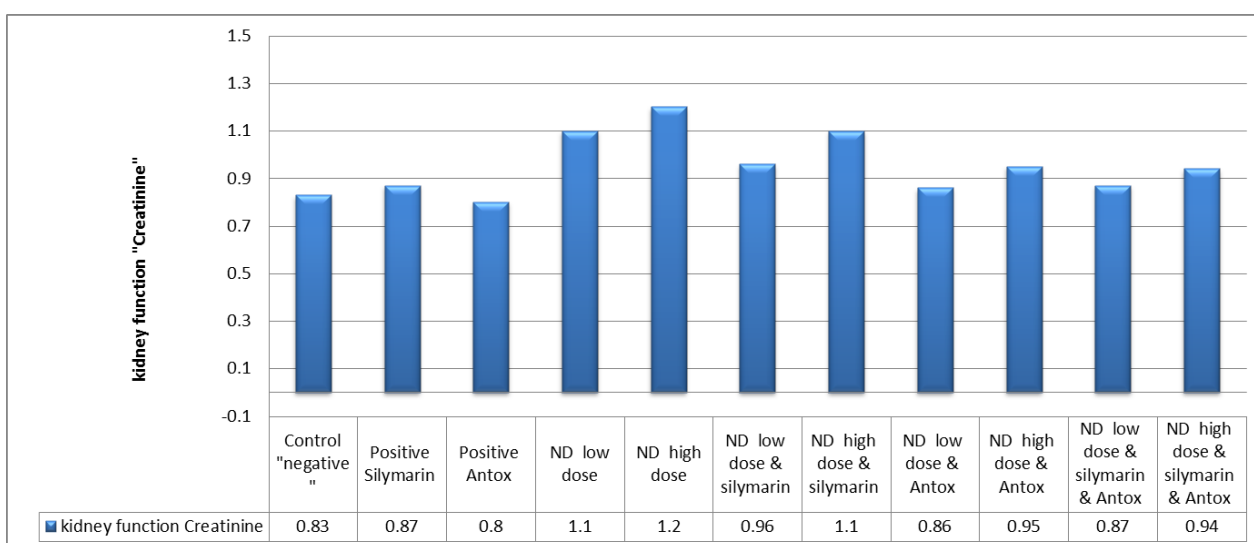


Figure 9: Shows the variation in creatinine level according to types of treatment groups of the rats.

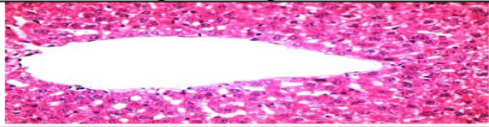
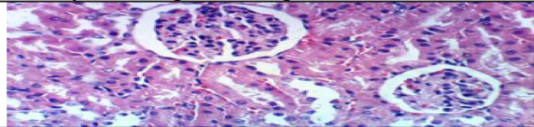
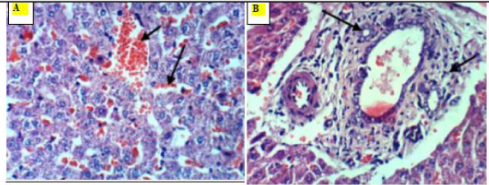
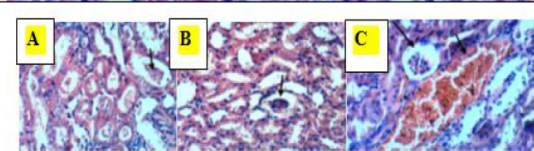
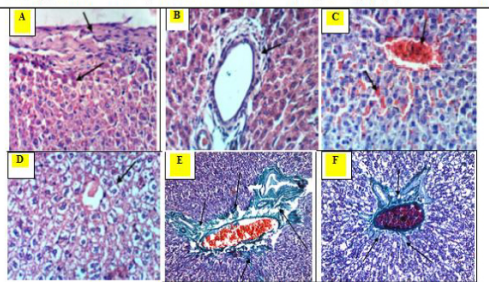
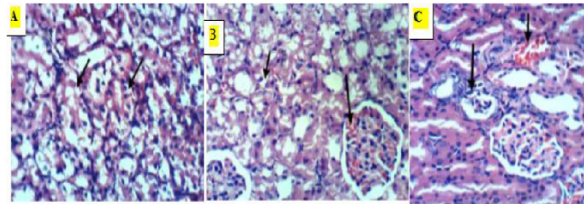
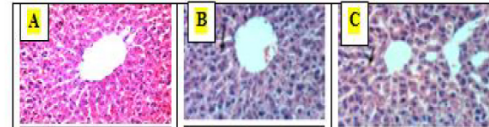
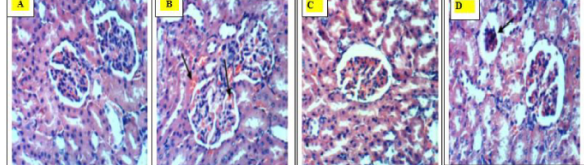
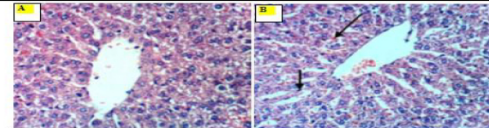
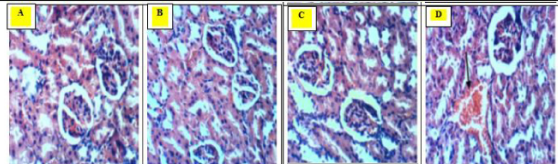
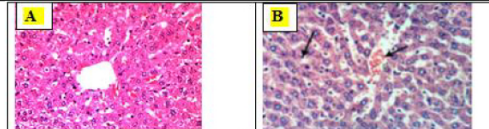
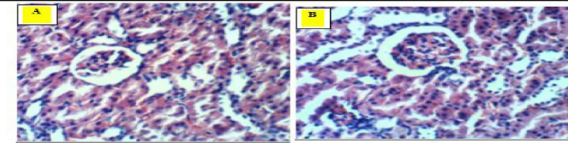
| Group | Liver Histological change | Kidney Histological change |
|--|---|---|
| Control negative, Silymarin & Antox |  |  |
| ND low dose |  <p>Livers of rats from group ND Low dose showing congestion of central vein (short arrow) and hepatic sinusoids (long arrow) (A), cholangitis (short arrow) with appearance of newly formed bile ductules (long arrow) (B) (H & E X 400).</p> |  <p>Kidneys of rats from group ND low dose showing protein material in the lumen of renal tubules (A), atrophy of glomerular tuft (B), congestion of renal blood vessel (short arrow) and atrophy of glomerular tuft (long arrow) (C).</p> |
| ND high dose |  <p>Livers of rats from group ND high dose showing thickening of hepatic capsule (short arrow) and necrosis of subcapsular hepatocytes (long arrow) (A), cholangitis (B), severe congestion of central vein and hepatic sinusoids (C), hydropic degeneration of hepatocytes (D) (H & E X 400). Hepatic periportal fibrosis is seen in (E) X 200 and (F) X 400 (Masson trichrome).</p> |  <p>Kidneys of rats from group ND high dose showing vacuolation of epithelial lining renal tubules (A), vacuolation of epithelial lining renal tubules (short arrow) and congestion of glomerular tuft (long arrow) (B), congestion of renal blood vessel (short arrow) and atrophy of glomerular tuft (long arrow) (C) (H & E X 400).</p> |
| ND low and high dose & Silymarin |  <p>Liver of rat from group ND low dose with Silymarin showing no histopathological changes (A). Livers of rats from group ND high dose with Silymarin showing slight activation of Kupffer cells (B) and slight congestion of hepatic sinusoids (C) (H & E X 400).</p> |  <p>Kidneys of rat from group ND low dose with Silymarin showing no histopathological changes (A), and another rat from the same group showing congestion of intertubular blood capillaries and glomerular tufts (B). Kidney of rat from group ND high dose with Silymarin showing no histopathological changes (C), and another rat from the same group showing slight atrophy of glomerular tuft (D) (H & E X 400).</p> |
| ND low and high dose & Antox |  <p>Liver of rat from group ND Low dose with Antox showing no histopathological changes (A). Liver of rat from group ND high dose with Antox showing slight activation of Kupffer cells (short arrow) and slight congestion of hepatic sinusoids (long arrow) (B) (H & E X 400).</p> |  <p>Kidneys of rats from group ND low dose with Antox showing no histopathological changes (A & B). Kidney of rat from group ND high dose with Antox showing no histopathological changes (C), and another rat from the same group showing congestion of renal blood vessel (D) (H & E X 400).</p> |
| ND low and high dose & Silymarin & Antox |  <p>Liver of rat from group ND low dose with Antox & Silymarin showing no histopathological changes (A). Liver of rat from group ND high dose with Silymarin & Antox showing slight congestion of central vein and activation of Kupffer cells (H & E X 400).</p> |  <p>Kidney of rat from group ND low dose with Silymarin & Antox showing no histopathological changes (A), and kidney of rat from group ND high dose with Silymarin & Antox showing also no histopathological changes (B) (H & E X 400).</p> |

Figure 10: Hepatic and renal histological change in different study group.

Figure 10 represents Hepatic and renal histological change in different study group.

Table 1 represents the percentage of hepatic histological changes in the different study groups. The table illustrates that there is statistically significance difference with p-value <0.05 in rats' liver histopathology

in different study group with high effect on liver tissues among groups takes ND low and high dose, and ND high dose & Antox.

| Group | No change | Pathological change | P-value |
|----------------------------------|-----------|---------------------|---------|
| | No. (%) | No. (%) | |
| Control "negative" | -100% | 0% | <0.001 |
| Positive Silymarin | -100% | 0% | |
| Positive Antox | -100% | 0% | |
| ND low dose | 0% | -100% | |
| ND high dose | 0% | -100% | |
| ND low dose & Silymarin | -100% | 0% | |
| ND high dose & Silymarin | -70% | -30% | |
| ND low dose & Antox | -100% | 0% | |
| ND high dose & Antox | -50% | -50% | |
| ND low dose & Silymarin & Antox | -100% | 0% | |
| ND high dose & Silymarin & Antox | -80% | -20% | |

Table 1: Comparisons of liver histopathology in different study group.

The Table 2 represents the percentage of renal histological changes in the different study groups. The table illustrates that there is statistically significance difference with p-value <0.05 in rats' kidney

histopathology in different study group with high effect on kidney tissues among groups takes ND low and high dose, and ND high dose & Silymarin.

| Group | No change | Pathological change | P-value |
|----------------------------------|-----------|---------------------|---------|
| | No. (%) | No. (%) | |
| Control "negative" | -100% | 0% | <0.001 |
| Positive Silymarin | -100% | 0% | |
| Positive Antox | -100% | 0% | |
| ND low dose | 0% | -100% | |
| ND high dose | 0% | -100% | |
| ND low dose & Silymarin | -70% | -30% | |
| ND high dose & Silymarin | -80% | -20% | |
| ND low dose & Antox | -100% | 0% | |
| ND high dose & Antox | -80% | -20% | |
| ND low dose & Silymarin & Antox | -100% | 0% | |
| ND high dose & Silymarin & Antox | -100% | 0% | |

Table 2: Comparisons of kidney histopathology in different study group.

This relation represents the changes in liver pathology according to the variation in liver enzymes. The mean value, SD and p value are recorded in the following table. Table 3; illustrates that there is statistically significant relation with p-value <0.05 in rats' liver histopathology in different study group with high mean of AST, ALT and bilirubin level among rats show liver pathology. According to this

relation the determination of liver enzymes can be marked for the pathological changes in the liver.

This relation represents the changes in kidney pathology according to the variation in kidney function tests. The mean value, SD and p value are recorded in the following table. Table 4; illustrates that there

is statistically significant relation with p-value <0.05 in rats' kidney histopathology in different study group with high mean of urea and creatinine level among rats show kidney pathology. According to this relation the determination of kidney function tests can be marked for the pathological changes in the kidney.

| Group | No change (n=71) | Pathological change (n=24) | P-value |
|-----------|------------------|----------------------------|---------|
| | Mean ± SD | Mean ± SD | |
| ALT | 32.4 ± 11.3 | 51.6 ± 7.1 | <0.0001 |
| AST | 48 ± 16 | 68.3 ± 5.2 | <0.0001 |
| Bilirubin | 0.87 ± 0.19 | 1.1 ± 0.12 | <0.0001 |

Table 3: The relation between liver enzymes with liver histopathology.

| Group | No change (n=71) | Pathological change (n=24) | P-value |
|------------|------------------|----------------------------|---------|
| | Mean ± SD | Mean ± SD | |
| Urea | 23.6 ± 3.1 | 31.8 ± 6.2 | <0.0001 |
| Creatinine | 0.93 ± 0.12 | 1.13 ± 0.13 | <0.0001 |

Table 4: The relation between kidney function tests with kidney histopathology.

Discussion

Nandrolone Decanoate (ND) According to the National Institute on Drug Abuse [9] is one of the most used anabolic derivatives of testosterone, because of its moderate androgenic potential associated with the best anabolic properties. Moreover, the use of Nandrolone Decanoate has been applied for therapeutic purposes, and has been effective, for example, to reduce loss of body mass and muscle in HIV patients, increase the number of satellite cells per muscle fibre and control of refractory anemia [10].

According to the main aim of this thesis, Silymarin and Antox are used to reduce the side effect of ND; Silymarin possesses antioxidant properties that seem to be due to their ability to scavenge free radicals and to chelate metal ions [11]. Antox is an antioxidant drug used in therapy of different liver diseases [8].

Regarding to the body weight, the groups which treated by ND at low and high dose showed the highest increase (142.3 g) in weight gain at different interval times. The increases in the body weight in presence at low dose of ND and this finding are agree with other research who stated that, the body mass was significantly higher in the ND low dose group received 5 mg/kg [12]. The increases in the body weight at ND high dose and this finding are agree with results of other study who reported that, the weight gain significantly increased compared with those of male and female control groups [13]. Another research stated that, ND treated rats was significantly higher than those of the control group [14].

Regarding to the liver weight, the highest increase of the liver weight showed in the case of low dose of ND recorded (4.9 ± 0.15 g) due to congestion and this behaviour dramatically change at high dose of ND which showed decrease in liver weight to (3.5 ± 0.09 g) that is due to

fibrosis as shown in histopathological effects of ND. This was in agreement with other study, who observed that the amount of collagen importantly increased in parenchyma of rat liver, following above the pharmacological dose of ND along five weeks [12], while other research, reported that liver weight of ND administered rats was higher as compared to control [15]. Similarly, another study reported that liver weight of ND administered rats increased at the rate of 19-36% [16]. However, observed that the liver weight of ND administered rats was lower as compared to control groups at the sixth week of the ND application [17]. In the another [18] study, the decrement of relative liver weight of ND administered rats was consistent with the observation of other research who suggested that this decrement may be due to the type of anabolic steroid, the form and duration of administration of the drug [17].

The combination of ND with Antox and Silymarin is success in reducing the damage effect of ND on the liver weight, where the results of liver weight at ND low dose with Antox and Silymarin recorded (3.8 ± 0.17 g) while the liver weight at ND high dose with Antox and Silymarin recorded (3.98 ± 1.5 g).

Regarding to the kidney weight, the highest weight of kidneys compared to another group weight at high dose of ND which recording 0.50 ± 0.005 g and 0.52 ± 0.005 g for right and left kidney respectively. This mainly due to congestion and this agrees with another study, described that the administration of 10 and 50 mg ND increased body weight, diameter and weight of the kidney at the end of 8th week of the experiment [19]. Additionally, other study showed that animals treated with Nandrolone had the kidney weight increased by about 30% [20].

Regarding to the liver enzymes, the variation in ALT, AST and bilirubin values showed higher values in the group treated with ND high dose and this behaviour is repeated in ND low dose group with lower increases. This in agreement with other research, who considered that the Nandrolone Decanoate management leads to a dose-dependent increase in serum levels of the aspartate aminotransferase and alanine aminotransferase in male rats [12]. Similarly, other study, showed that serum aspartate transaminase (AST) value in female and male test groups were significantly increased [13].

Regarding to the kidney function was normal in all control groups while highly increased in ND high dose and this behaviour is repeated in low dose ND with a lower increase in Urea. This agrees with other study, who reported that is increase in urea concentration with groups treated with ND and ND+BOL (Boldenone) (1-dehydro derivative of testosterone) for six weeks a similar trend was found for Creatinine concentrations [21].

Regarding to the liver histology in this study showing no changes occur in the control groups but the groups treated by ND showed histopathological changes in the liver tissue. These changes in liver histopathology agree with other research, demonstrated that 5-week ND administration at three different dosages (0.7 mg/kg, 5.3 mg/kg and 10.3 mg/kg) per week in rats leads to an increase in collagen deposition in the liver parenchyma, portal space, and centrolobular vein [12].

Regarding the kidney histology, this study detected no pathological changes occur in the all control groups, on the other hand the groups treated by ND showed pathological changes in renal tissues. This was in agreement with another study, who studied the effects of testosterone undecanoate (TU) treatment reported degeneration of the kidney were found in 25% of the animals treated with TU [22,23].

Conclusion

The combination of Silymarin and Antox with ND showed the best improvement in liver and renal tissues changes, these means synergistic action to protect the hepato-renal cells against harmful effect of ND by their antioxidant and free radical scavenging activities. No reported research studied the effect of combination of Silymarin and Antox with ND.

References

1. Kicman AT (2008) Pharmacology of anabolic steroids. *Br J Pharmacol* 154: 502-521.
2. Strawford A, Barbieri T, Van Loan M (1999) Resistance exercise and supraphysiologic androgen therapy in eugonadal men with HIV-related weight loss: A randomized controlled trial. *JAMA* 281: 1282-1290.
3. Parssinen M, Seppala T (2002) Steroid use and long term risk to health in former athletes. *Sports Med* 32: 83-94.
4. Eklof AC, Thurelius AM, Garle M, Rane A, Sjoqvist F (2003) The anti-doping hot-line, a means to capture the abuse of doping agents in the Swedish society and a new service function in clinical pharmacology. *Eur J Clin Pharmacol* 59: 571-577.
5. Cuerda C, Zugasti A, Bretón I, Camblor M, Miralles P, et al. (2005) Treatment with nandrolone decanoate and megestrol acetate in HIV-infected men. *Nutr Clin Pract* 20: 93-97.
6. Fortunato RS, Marassi MP, Chaves EA, Nascimento JHM, Rosenthal D, et al. (2006) Chronic administration of anabolic androgenic steroid alters murine thyroid function. *Med Sci Sports Exerc* 38: 256-261.
7. Saller R, Meier R, Brignoli R, (2008) The use of Silymarin in the treatment of liver disease. *Drugs* 61: 2034-2061.
8. Oz HS, McClain CJ, Nagasawa HT, Ray MB, deVilliers WJ, et al. (2004) Diverse antioxidants protect against acetaminophen hepatotoxicity. *J Biochem Mol Toxicol* 18: 361-368.
9. NIDA (2000) Research Report-Steroid abuse and addiction: NIH Publication No. 37, p: 21.
10. Shahidi NT (2001) A review of the chemistry, biological action, and Clinical applications of anabolic-androgenic steroids. *Clin Ther* 23: 1355-1390.
11. Allouh MZ, Rosser BW (2010) Nandrolone decanoate increases satellite cell numbers in the chicken pectoralis muscle. *J Histol Histopathol* 25: 133-140.
12. Borsari M, Gabbi C, Ghelfi F, Grandi R, Saladini M, et al. (2001) Silybin, a new iron chelating agent. *J Inorg Biochem* 85: 123-129.
13. Vieira RP, Franca RF, Damaceno-Rodrigues NR, Dolhnikoff M, Caldini EG, et al. (2008) Dose-dependent hepatic response to subchronic administration of Nandrolone Decanoate. *Med Sci Sport Exer* 40: 842-847.
14. Shahraki MR, Rafeei R (2015) The Effects of Subacute Supraphysiological Dose of Nandrolone Decanoate on Liver Enzymes and Lipid Profiles in Rats. *Zahedan J Res Med Sci* 17: 4.
15. Mobini Far HR, Agren G, Lindqvist AS, Marmendal M, Fahlke C, et al. (2007) Administration of the anabolic androgenic steroid nandrolone decanoate to female rats causes alterations in the morphology of their uterus and a reduction in reproductive capacity. *Eur J Obstet Gynecol* 131: 189-197.
16. Gerez JR, Frei F, Cristina I, Camargo C (2005) Histological assessment of ovaries and uterus of rats subjected to Nandrolone Decanoate treatment. *Contraception* 72: 77-80.
17. Karbalay-Doust S, Noorafshan A (2009) Stereological study of the effects of nandrolone decanoate on the mouse liver. *Micron* 40: 471-475.
18. Yu-Yahiro JA, Michael RH, Nasrallah DV, Schofield B (1989) Morphologic and histologic abnormalities in female and male rats treated with anabolic steroids. *Am J Sports Med* 17: 686-689.
19. Tasgin E, Haliloglu S (2013) The Administration of nandrolone decanoate may cause multiple organ failure. *Sci Movement Health* 13: 784-788.
20. Minkin DM, Meyer ME, Van Haaren F (1993) Behavioral effects of long-term administration of an anabolic steroid in intact and castrated male Wistar rats. *Pharmacol Biochem Behav* 44: 959-963.
21. Hoseini L, Roozbeh J, Sagheb M, Karbalaydoust S, Noorafshan A (2009) Nandrolone Decanoate increases the volume but not the length of the proximal and distal convoluted tubules of the mouse kidney. *Micron* 40: 226-230.
22. Shabir N, Malik H, Sajjad S, Abbas MN (2015) Effect of Nandrolone Decanoate, Boldenone Undecylenate on Renal Status of Rabbits. *Global Veterinarian* 14: 432-438.
23. Bento-Silva MT, Martins MDCDCE, Torres-Leal FL, Barros TL, Carvalho ILDNFD, et al. (2010) Effects of administering testosterone undecanoate in rats subjected to physical exercise: effects on the estrous cycle, motor behavior and morphology of the liver and kidney. *Braz J Pharm Sci* 46: 79-89.



America: OMICS International Journals / Authorproofs
5716 Corsa Ave, Suite 110, Westlake
Los Angeles, CA 91362-7354, USA

UK: OMICS International
Heathrow Stockley Park Lakeside
House, 1 Furzeground Way
Heathrow, UB11 1BD, UK

Europe: OMICS International
Traian Str., No.61
Constanta 900720, Romania

America: Tel: +1-888-843-8169, 1-650-268-9744, Fax: +1-650-618-1417

UK: Tel: +1-800-216-6499; **Europe:** Tel: + 0805-080048

Conferences by Country

| | |
|---|---|
|  USA |  Malaysia |
|  Australia |  Singapore |
|  UAE |  South Africa |
|  Italy |  New Zealand |
|  Germany |  Philippines |
|  UK |  Poland |
|  Japan |  Austria |
|  Brazil |  Turkey |
|  South Korea |  Finland |
|  Netherlands |  Ukraine |
|  Spain |  Denmark |
|  Canada |  Mexico |
|  Switzerland |  Norway |
|  France |  China |
|  India | |

Clinical & Medical Journals

| | |
|--------------------------|----------------------------------|
| Anesthesiology | Neurology |
| Cardiology | Nursing |
| Clinical Research | Nutrition |
| Dentistry | Oncology |
| Dermatology | Ophthalmology |
| Diabetes & Endocrinology | Orthopaedics |
| Gastroenterology | Pathology |
| Haematology | Pediatrics |
| Health Care | Physicaltherapy & Rehabilitation |
| Immunology | Psychiatry |
| Infectious Diseases | Pulmonology |
| Medicine | Reproductive Medicine |
| Microbiology | Surgery |
| Nephrology | Toxicology |